chapter 16

The Frontal Lobes

E. L. was a professor of botany at a college in upstate New York. Known for his organizational skills, E. L. had developed a large herbarium at the college and truly enjoyed having students working with him on various research projects. Late in the spring semester when he was 60 years old, E. L. began to have headaches and felt as if he had the flu; after a few days bed rest, however, he was not getting any better. He eventually visited his physician, who determined that E. L. had an infection, although the source was difficult to identify.

Meanwhile, E. L. began to develop cognitive symptoms that his wife found very worrisome. He seemed disorganized, showed little emotion, and, although a chapter of his unpublished book was due and he was never late in doing such things, he said that he just could not think of anything to write.

The most striking thing about E. L. when he arrived for his neuropsychological assessment was his flat affect and the virtual absence of facial expression—symptoms typical of left-frontal-lobe patients. This lack of affect was not associated with a lack of effort on the tests, however, because the assessment ranked his intelligence and general memory scores in the superior range. He did, nevertheless, register significant impairments on tests sensitive to frontal-lobe functions.

Talking with E. L. and his wife of more than 30 years made it clear that E. L. was having difficulty not only with his academic work but also with his social interactions with colleagues, friends, and his family. He found it difficult to interact even with close friends, and his wife was concerned that her husband was "not the man I married."

In a real sense, all neural roads eventually lead to the frontal lobes. As is apparent in E. L.'s case, when some of the roads lead nowhere, people can have major problems in generating appropriate behavior. In this chapter, we consider the anatomical organization of the frontal lobes, including the neural roads for information flow to and from them, before looking at a general theory of frontal-lobe function, the various symptoms associated with frontal-lobe injury, and diseases that affect the frontal lobes.

Anatomy of the Frontal Lobes

Children are notorious for their social faux pas because they do not recognize that the rules of behavior change with the social and environmental circumstances. Indeed, controlling our behavior in response to the social or environmental situation that we are in requires considerable skill, and we can all relate examples in which we goofed and behaved inappropriately. Fortunately, most of us do not err often, because our frontal lobes control our behavior with respect to time and place. Yet the frontal lobe can perform such a function only if it is provided with all the relevant sensory and mnemonic (that is, memory) information available.

Subdivisions of the Frontal Cortex

In the human brain, the frontal lobes comprise all the tissue in front of the central sulcus. This vast area, constituting 20% of the neocortex, is made up of several functionally distinct regions that we shall group into three general categories—motor, premotor, and prefrontal (Figures 16.1 and 16.2).

The motor cortex is area 4. The premotor cortex includes areas 6 and 8, which can be divided into four regions:

lateral area 6: premotor cortex

medial area 6: supplementary motor cortex

area 8: frontal eye field

area 8A: supplementary eye field

In humans, the lateral premotor area expanded as Broca's area (area 44) developed.

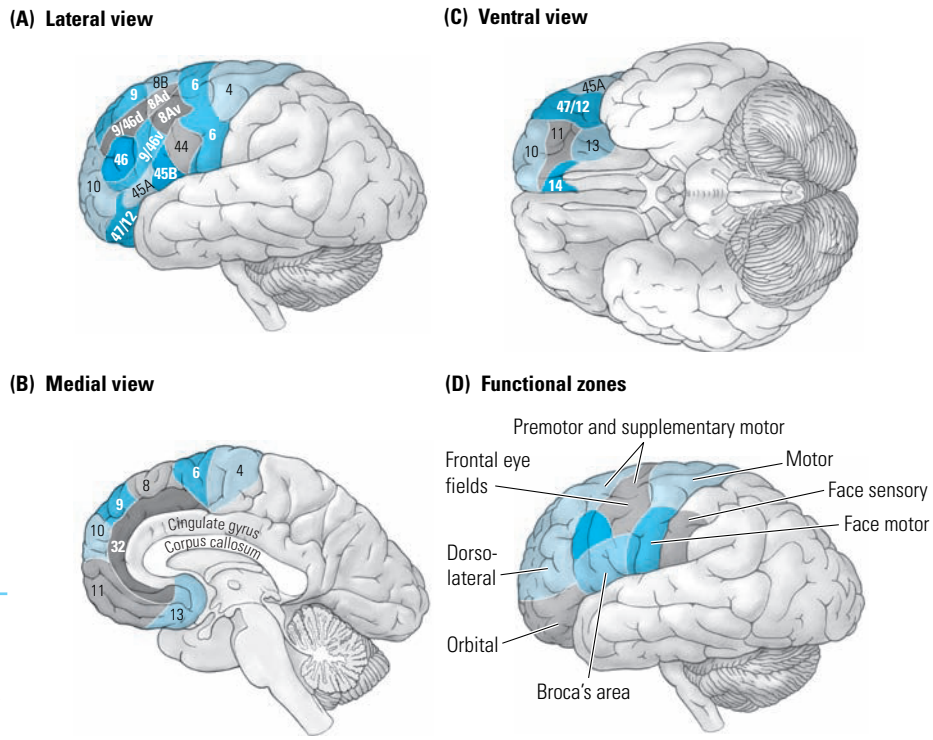

Figure 16.1 Petrides and Pandya's cytoarchitectonic map of the frontal lobe. Approximate boundaries of functional zones of the frontal lobe are shown in part D.

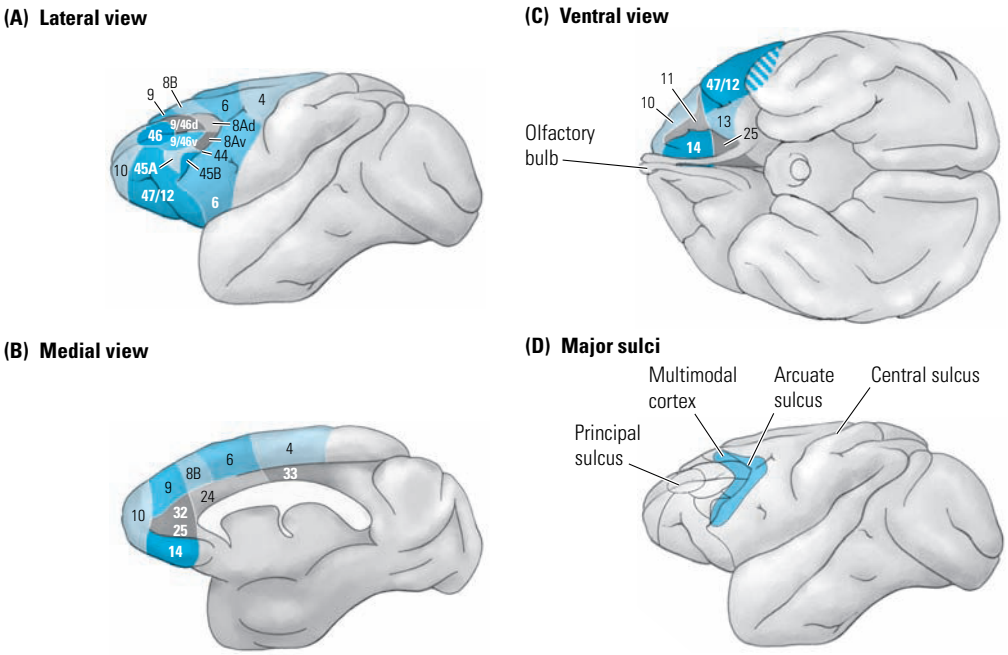

Figure 16.2 Petrides and Pandya's cytoarchitectonic map of the frontal lobe of the rhesus monkey. The two major sulci in the monkey frontal lobe are the principal sulcus and the arcuate sulcus, as shown in part D.

Prefrontal cortex is a peculiar name that derives from Jersey Rose and Clinton Woolsey's observation that the frontal lobes of all the mammalian species that they examined have a region that receives projections from the dorsomedial nucleus of the thalamus. They saw this thalamic projection as being parallel to the projections of the lateral and medial geniculate nuclei to the visual and the auditory cortex, respectively, and concluded that the dorsomedial projection could be used to define a similar region in different animal species. They termed this region the prefrontal cortex.

In primates, the prefrontal cortex can be divided into three regions (refer to Figures 16.1 and 16.2): (1) dorsolateral prefrontal cortex (areas 9 and 46); (2) inferior (ventral) prefrontal cortex (areas 11, 12, 13, and 14); and (3) medial frontal cortex (areas 25 and 32). The inferior frontal cortex is sometimes referred to as the **orbital frontal cortex** because of its relation to the orbit (eye socket). The medial frontal area is sometimes considered part of the anterior cingulate region rather than part of the prefrontal cortex, even though it may receive dorsomedial projections.

As in the temporal lobe, many areas in the frontal lobe are multimodal. Cells responsive to combinations of visual, auditory, and somatic stimuli are found in the lateral premotor cortex (area 6) and in area 46. In contrast, cells responsive to taste and olfaction are found in area 13. The latter cells likely produce our perception of flavor in foods.

Connections of the Motor and Premotor Areas

The motor and premotor areas are part of a functional system to control movements directly. Several groups of connections bind up this system:

- The motor cortex projects to the spinal motor neurons to control limb, hand, foot, and digit movements and to the appropriate cranial nerve motor neurons to control facial movements. It also projects to other motor structures such as the basal ganglia and the red nucleus.

- The premotor areas can influence movement directly through corticospinal projections or indirectly through projections to the motor cortex. The premotor regions also receive projections from the posterior parietal areas PE and PF. Thus, the premotor regions are connected to areas concerned with the execution of limb movements.
- The frontal eye fields (areas 8 and 8A) receive projections from regions controlling eye movements and send projections to these regions. Thus, these regions receive visual input from posterior parietal region PG and the superior colliculus.
- All premotor areas receive projections from the dorsolateral prefrontal cortex, which implies that this prefrontal area has some role in the control of limb and eye movements.

Connections of the Prefrontal Areas

The prefrontal areas can be viewed as the end points of the dorsal (object recognition) and ventral (spatial behavior) visual streams. In fact, Felleman and van Essen included prefrontal regions as part of the visual cortex (see Figure 10.19).

The dorsolateral prefrontal cortex (areas 9 and 46) receives its main inputs from the posterior parietal areas and the superior temporal sulcus. These connections are reciprocal. In addition, the dorsolateral cortex has extensive connections to regions to which the posterior parietal cortex also projects, including the cingulate cortex, basal ganglia, and superior colliculus (see Figure 14.2). The key to understanding the functions of the dorsolateral cortex lies in its relation to the posterior parietal cortex (Figure 16.3A).

The orbital frontal cortex (areas 11 through 14) receives its main afferents from the temporal lobe, including the auditory regions of the superior temporal gyrus, the visual regions of TE and the superior temporal sulcus, and the amygdala (Figure 16.3B). In addition, there are connections from the somatosensory cortex (area 43), gustatory cortex (in the insula), and olfactory regions of the pyriform cortex, as illustrated in Figure 16.4. The orbital cortex therefore gains input from all sensory modalities. The orbital frontal area projects subcortically to the amygdala and hypothalamus, providing a route for influencing the autonomic system, which controls changes in blood pressure, respiration, and so on. These physiological changes are important in emotional responses.

Figure 16.3 The corticocortical connections to the frontal lobe of the rhesus monkey (see Figure 16.2). (A) The connections to the dorsolateral surface include projections from posterior parietal as well as temporal regions. (B) The connections to the inferior frontal region are from the temporal lobe. Connections from the insula and olfactory cortex are not shown.

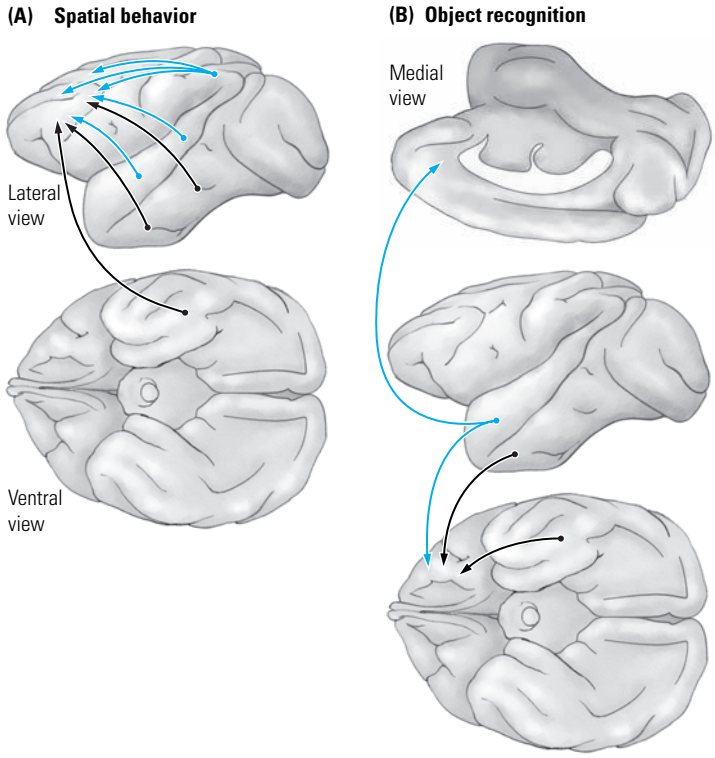

The prefrontal regions receive significant input from dopaminergic cells in the tegmentum. This modulatory input plays an important role in regulating how prefrontal neurons react to stimuli, including stressful stimuli, and probably plays some role in our different emotional states. Abnormalities in this projection play a central role in schizophrenia.

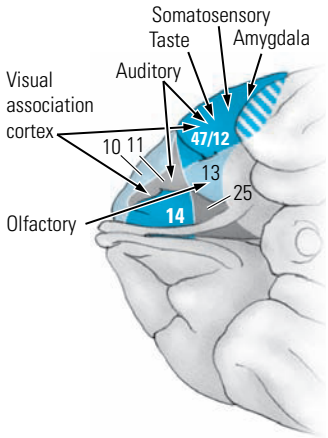

Figure 16.4 Inputs to the orbitofrontal cortex. Schematic illustration of the ventral surface of the monkey orbitofrontal cortex, including inputs from all sensory regions. (After Rolls, 1998.)

A Theory of Frontal-Lobe Function

Imagine the following scenario. At the last moment, you have invited friends for dinner. Because you have nothing to serve, you must go shopping after you leave work at 5:00 P.M. Before leaving, you prepare a list of items to buy. You are working under a time constraint because you must return home before your guests arrive and you need time to prepare. Because the items you need are not all at the same store, you must make an efficient plan of travel. You also must not be distracted by stores selling items (such as shoes) that you do not need or by extended chats with store clerks or friends whom you might encounter.

The task that you have set yourself is a bit rushed, but for most people it offers little challenge. People with frontal-lobe injury, however, cannot manage it. The fundamental requirements of the task that challenge frontal-lobe patients are as follows:

- Planning in advance and selecting from many options
- Ignoring extraneous stimuli and persisting in the task at hand
- Keeping track of the stores to which they have gone and the items that they have already purchased

The behavioral requirements of this task can be described as the temporal organization of behavior, and this organization is the general function of the frontal lobe. Thus, the frontal lobe contains control systems that implement different behavioral strategies in response to both internal and external cues. In recent years, it has become fashionable to refer to these temporal systems as *executive functions*, although we do not want to read too much into this label. The premotor and prefrontal regions contribute in different ways to this control function, and so we will consider them separately.

Functions of the Premotor Cortex

Whereas the motor cortex provides a mechanism for the execution of individual movements, the premotor cortex selects the movements to be executed. Consider the behavior of a resting dog. It may get up and respond to its owner's call or it may get up for no apparent reason and wander about the yard.

The former movements are made in response to a specific environmental cue, whereas the latter behavior can be regarded as a response to an internal event. Passingham suggested that the premotor region functions primarily to

choose behavior in response to external cues and the supplementary motor region makes a greater internal contribution when no such cues are available.

Just as we choose limb movements, we must select eye movements. This selection is the function of the frontal eye fields. Like limb movements, eye movements can be made to specific targets that are visible or they can be made on the basis of internal cues. Thus, we can make eye movements to look at specific objects or we can gaze around, seemingly without purpose. Passingham suggested that area 8 is specialized for stimulus-directed movements, whereas area 8A is responsible for internally driven movements.

The role of the premotor cortex in response selection was first shown in normal subjects by Roland and his colleagues. They compared the cerebral blood flow in subjects making either a repetitive movement of one finger or a complex sequence of 16 movements of the fingers of one hand. The increase in blood flow in the supplementary motor cortexes *in both hemispheres* was larger in the sequence task than in the repetitive task. There was, however, no increase in blood flow in the premotor region.

Roland concluded that the supplementary motor region plays a special role in the selection and direction of motor sequences. An important aspect of Roland's experiment is that there was no external cue for the movements. That is, the production of the movement sequence was self-paced, or internally driven.

Deiber and colleagues showed that the premotor cortex is activated when movement sequences are paced externally by a cue. In their experiment, the subjects performed one of two tasks. In the first task, whenever a tone sounded, they made a fixed movement, which was to move a joystick forward. In this case, there was no response selection; the same response was made each time. In the second task, when the subjects heard the tone, they randomly made one of four movements of the joystick (forward, backward, left, or right). This task required a choice of movement. The results showed a significant effect of response selection: there was an increase in blood flow to both premotor areas in the choice condition relative to the fixed condition.

It is curious that both premotor regions were activated in the Deiber task, but an experiment by Jenkins and colleagues may provide an explanation. These researchers compared the performance of a prelearned sequence of finger movements with the learning of a sequence in which a tone indicated whether the sequence was correct or incorrect. The medial region was relatively more activated during the prelearned sequence, and the lateral region was more activated during the learning sequence. It seems likely that, during the prelearned movement, the cues were internal, whereas, on the learning task, the subjects had to attend to external cues.

Functions of the Prefrontal Cortex

The motor cortex is responsible for making movements. The premotor cortex selects movements. The prefrontal cortex controls cognitive processes so that appropriate movements are selected at the correct time and place. This selection may be controlled by internalized information or external cues or it may be made in response to context or self-knowledge. We consider these aspects separately.

Internal Cues

The internalized record of what has just taken place is independent of the existing sensory information and can be called *temporal memory*, *working memory*, or *short-term memory*. We use **temporal memory** here to refer to a neural record of recent events and their order. These events may be related to things or to movements and thus derive their information from the object-recognition or motor streams of sensory processing.

Recall that both streams project to the prefrontal cortex, although to different places (see Figure 16.3), which suggests temporal memory for both motor and object information, although the memory will be localized in different places in the frontal cortex. The dorsolateral areas are especially engaged in the selection of behavior based on temporal memory.

External Cues

People whose temporal memory is defective become dependent on environmental cues to determine their behavior. That is, behavior is not under the control of internalized knowledge but is controlled directly by external cues. One effect of this condition is that people with frontal-lobe injuries have difficulty in inhibiting behavior directed to external stimuli. In our dinner-party example, frontal-lobe patients would enter a shoe store or chat with friends as they responded to environmental cues that they encountered. (We have probably all experienced occasions when the temporal organization of our behavior failed and we were controlled by external cues rather than internalized information. How many times have you started to do something, been distracted by a question or event, and then been unable to recall what you were going to do? Sadly, this phenomenon increases with age, which is not reassuring information about the state of one's prefrontal cortex.)

One type of environmental cue is feedback about the rewarding properties of stimuli. For example, if you imagine that a certain stimulus, such as a photograph of your grandmother, is always associated with a reward, such as wonderful food, then you learn the association between the visual stimulus (the photograph of grandma) and the reinforcement (food). The learning of such associations is central to much of what we do as we learn about the world, and the orbital cortex is central to learning by associations.

Context Cues

We humans live complex lives. We live in social groups in which we have multiple simultaneous roles as children, parents, friends, siblings, lovers, workers, and so on. Each of these roles is governed by rules of behavior that we are expected to follow: our behavior around our grandparents is certainly different from our behavior with our high-school friends. Similarly, our behavior varies with the environment: we are quiet at a movie theater or in a library, but we may be noisy at a football game or at a picnic.

Behavior, then, is context dependent. Hence, behavior that is appropriate at one moment may not be appropriate if there are subtle changes in the context. This point is beautifully illustrated in Jane Goodall's graphic descriptions of the different behavioral patterns exhibited by chimpanzees. The makeup of the social group at any given time dictates the behavior of each

chimpanzee. Given the presence and position of certain animals, a particular chimp may be bold and relaxed, whereas, with a different group of animals, the chimp is quiet and nervous. Further, an error in evaluating the context can have grievous consequences.

It may be no accident that the frontal lobe has grown so large in primates that are highly social. We can easily see the importance of social context when we reflect on our behavior with our grandparents versus that with our closest friends. It is common experience that our tone of voice, the use of slang or swear words, and the content of conversations are quite different in the two contexts.

The choice of behaviors in context requires detailed sensory information, which is conveyed to the inferior frontal cortex from the temporal lobe. Context also means affective context, and this contribution comes from the amygdala. People with orbital frontal lesions, which are common in closed-head injuries (damage that results from a blow to the head), have difficulty with context, especially in social situations, and are notorious for making social gaffes. Closed-head injuries are considered in detail in Chapter 26.

Autonoetic Awareness

Not only is our behavior under the control of ongoing sensory input, temporal memory, and context, but it is also affected by a lifetime of experiences and goals. Tulving called this autobiographical knowledge **autonoetic awareness** (that is, self-knowing). Tulving's idea is that autonoetic awareness makes it possible to bind together the awareness of oneself as a continuous entity through time.

Impairment in autonoetic awareness results in a deficit in the self-regulation of behavior. Thus, our behavior is under the influence of our personal past experiences and life goals for the future such that we interpret the world in our daily life within our own frames of reference. Patients with orbital frontal injury often lose this self-knowledge and have real difficulty in daily living. Levine and colleagues described M. L., a salesman whose orbital frontal injury resulted from a closed-head injury. M. L. noted that maintaining a close relation with his wife of 10 years was very difficult. "I have a hard time relating to my wife. I don't know why I married this person. . . . I told myself I must have been happy, and they said I was." This type of symptom surely would be very disruptive to daily living, but it is not easy to capture with a neuropsychological test, in part because the symptoms are so individual.

Asymmetry of Frontal-Lobe Function

In keeping with the general complementary organization of the left and right hemispheres, as a rule the left frontal lobe has a preferential role in language-related movements, including speech, whereas the right frontal lobe plays a greater role in nonverbal movements such as facial expression. Like the asymmetry of the parietal and temporal lobes, the asymmetry of frontal-lobe function is relative rather than absolute; the results of studies of patients with frontal lesions indicate that both frontal lobes play a role in nearly all behavior. Thus, the laterality of function disturbed by frontal-

Table 16.1 Relative frequency of defective performance on neuropsychological tests

	PERCENTAGE OF GROUP SHOWING A DEFICIT		
Test	Left hemisphere (%)	Right hemisphere (%)	Bilateral (%)
Verbal fluency	70	38	71
Verbal learning	30	13	86
Block construction	10	50	43
Design copying	10	38	43
Time orientation	0	0	57
Proverbs	20	25	71

Source: After Benton, 1968.

lobe lesions is far less striking than that observed from lesions in the more-posterior lobes.

Nonetheless, as with the temporal lobe, there is reason to believe that some effects of bifrontal lesions cannot be duplicated by lesions of either hemisphere alone. Table 16.1 summarizes a study comparing the behavioral effects of unilateral and bilateral frontal lesions. People with bifrontal lesions are severely impaired in reporting the time of day and in decoding proverbs, effects seldom seen subsequent to unilateral frontal lesions.

Recently, Tulving and his colleagues proposed that the left and right frontal lobes may play different roles in memory processing: the left prefrontal cortex is proposed to be have a greater role in encoding information into memory, whereas the right prefrontal cortex is more engaged than the left in retrieval. This hypothesis remains controversial, in part because it is difficult to fit such a finding with our notions of what cerebral asymmetry represents. We shall return to the Tulving proposal in Chapter 18 (for a review, see Lepage et al., 2000, and Tulving, 2002).

Heterogeneity of Frontal-Lobe Function

Shallice and Burgess noted that correlations among performance on tasks sensitive to frontal-lobe injury are relatively low. Among the many explanations offered for low interest correlations, one is that the tests require different cognitive operations for their successful solution. These different functions require different bits of the frontal lobe, and, given that the exact site of injury will vary among patients, the different tests are impaired to different degrees.

Thus, as we consider the different symptoms of frontal-lobe injury, we must remember that any individual patient is unlikely to show all the symptoms, and the severity of symptoms will vary with lesion location. Few imaging studies have addressed the matter of heterogeneity and, as we shall see, the trend has been for evidence favoring homogeneity of function. The Snapshot on page 401 shows, however, that, at least in the orbital frontal cortex, there is evidence of discrete localization of functions.

Symptoms of Frontal-Lobe Lesions

Of primary concern here are the effects of unilateral lesions to the frontal cortex. In an effort to organize the symptoms conceptually, we have grouped them into eight major categories (Table 16.2). We do not mean to imply that the brain respects these categories but rather that the categories provide a conceptual framework within which to consider the symptoms.

Disturbances of Motor Function

Frontal lesions can impair a person's ability to make a wide variety of movements, to order movement sequences, and even to speak.

Fine Movements, Speed, and Strength

Damage to the primary motor cortex is typically associated with a chronic loss of the ability to make fine, independent finger movements, presumably owing to a loss of direct corticospinal projections onto motor neurons. In addition, there is a loss of speed and strength in both hand and limb movements in the contralateral limbs. The loss of strength is not merely a symptom of damage to area 4, because lesions restricted to the prefrontal cortex also lead to a reduction in hand strength.

Movement Programming

In a classic paper in 1950, Karl Lashley asked how movements are put together in a particular order. How is it, he asked, that a violinist can play an arpeggio so quickly and flawlessly? Clearly, each note is not "thought of" separately. And how is it that, in a tennis game, a player can make very rapid movements, seemingly much too fast to have considered each movement by itself?

Lashley presumed that this function—serially ordering complex chains of behavior in relation to varying stimuli—must somehow be a function of the neocortex. Although he believed it to be a function of the entire neocortex, it appears more likely to be a function of the frontal lobes. Removal of the supplementary motor cortex results in a transient disruption of nearly all voluntary movements (including speech, if the removal is on the left). There is rapid recovery, however, and the only permanent disability appears to be in the performance of rapidly alternating movements with the hands or fingers.

The likely reason that relatively minor symptoms result from rather large supplementary motor lesions is that both the left and the right premotor cortexes participate in the control of movement. This idea is supported by observations that both left and right premotor areas show an increase in blood flow during unimanual tasks in humans; in monkeys, cells in both the left and the right areas show increased activity regardless of which hand is moving. There is also a bilateral projection from each supplementary motor cortex to the basal ganglia.

Further evidence favoring a role for the frontal cortex in movement programming comes from the results of a study by Kolb and Milner, in which patients with localized unilateral frontal lobectomies (most of which did not include the premotor cortex) were asked to copy a series of arm or facial movements (see Figure 14.8). Although the patients showed mild impairment in copying the arm

S N A P S H O T

Heterogeneity of Function in the Orbital Frontal Cortex

The orbital frontal cortex is a large region of the frontal lobe that includes at least five subregions—namely, Brodmann's areas 10 through 14. Different regions have different patterns of connectivity. Area 13, for example, has extensive connections with the amygdala and hypothalamus, whereas area 11 has connections with medial temporal cortical areas taking part in recognition memory.

The orbital frontal cortex is a challenge to study functionally in the laboratory because its location makes discrete lesions difficult to produce. Furthermore, although the orbital frontal cortex is often affected in closed-head injuries, these injuries are not focal but tend to be diffuse across the orbital region.

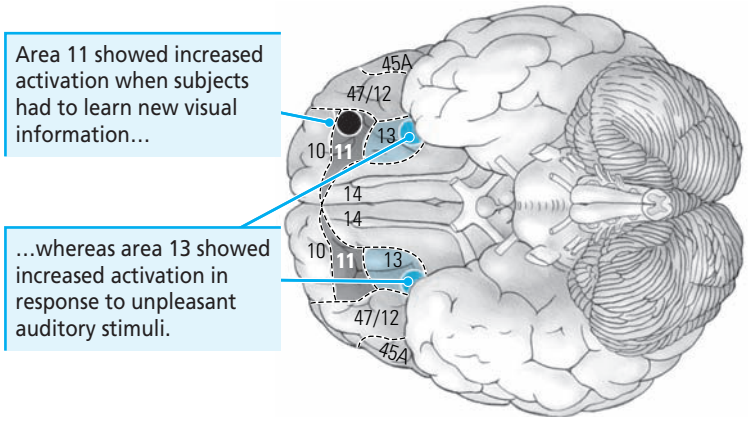

Activation of the orbital frontal cortex by sensory stimulation. (After Frey and Petrides, 2000, and Frey, Kostopoulous, and Petrides, 2000.)

Frey and Petrides examined functional heterogeneity in the orbital region in two parallel PET studies. In one study, subjects heard either the sounds of violent car crashes, which they suspected would be perceived as unpleasant, or familiar abstract sounds generated from an electronic keyboard. In the other study, the subjects were presented with novel abstract visual designs that they had to either commit to memory or just view. Abstract designs were used to prevent subjects from verbalizing the images and thus provoking semantic associations.

As shown in the adjoining figure, area 13 showed increased activation in response to the unpleasant auditory stimuli, whereas area 11 showed increased activation when subjects had to learn new visual information. These results show a clear functional dissociation of the two orbital regions: area 13 (richly connected to the amygdala and hypothalamus) processes unpleasant auditory information; area 11 (medial temporal cortical connections) processes the encoding of new visual information.

Area 13 can be seen as a region that can alert an organism to attend to stimuli that have affective qualities. We might predict that people with damage to area 13 would be less responsive to threatening stimuli, and they are. It would be interesting to determine whether both areas would be implicated if unpleasant stimuli were to be encoded.

(After S. Frey and M. Petrides. Orbitofrontal cortex: A key prefrontal region for encoding information. *Proceedings of the National Academy of Sciences of the United States of America* 97:8723–8727, 2000; S. Frey, P. Kostopoulous, and M. Petrides. Orbitofrontal involvement in the processing of unpleasant auditory information. *European Journal of Neuroscience* 12:3709–3712, 2000.)

movements, it was small compared with the performance of patients with left-parietal-lobe lesions. In contrast, patients with both left- and right-frontal-lobe damage were very poor at copying a series of facial movements.

An analysis of the facial-movement task showed that the groups with frontal-lobe lesions made more errors of sequence than did normal controls or other groups of patients. In other words, patients with frontal-lobe lesions had

Table 16.2 Summary of major symptoms of frontal-lobe damage

Most probable symptom	Lesion site	Basic reference
Disturbances of Motor Function		
Loss of fine movements	Area 4	Kuypers, 1981
Loss of strength	Areas 4 and 6; dorsolateral	Leonard et al., 1988
Poor movement programming	Premotor Dorsolateral	Roland et al., 1980 Kolb and Milner, 1981
Poor voluntary eye gaze	Frontal eye fields	Guitton et al., 1982
Poor corollary discharge	Dorsolateral, premotor	Teuber, 1964
Broca's aphasia	Area 44	Brown, 1972
Loss of Divergent Thinking		
Reduced spontaneity	Orbital	Jones-Gotman and Milner, 1977
Poor strategy formation	Dorsolateral?	Shallice, 1988
Poor frequency estimate	Dorsolateral	Smith and Milner, 1984
Environmental Control of Behavior		
Poor response inhibition	Prefrontal	Milner, 1964
Impaired associative learning	Dorsolateral	Petrides, 1997
Risk taking and rule breaking	Prefrontal	Miller, 1985
Gambling	Orbital	Bechara et al., 2000
Self-regulatory disorder	Orbital	Levine et al., 1998
Poor Temporal Memory		
Poor working memory	Dorsolateral	Petrides, 2000
Poor delayed response	Dorsolateral	Freedman and Oscar-Berman, 1986a
Other Symptoms		
Impaired social behavior	Orbital; dorsolateral	Blumer and Benson, 1975
Altered sexual behavior	Orbital	Walker and Blumer, 1975
Impaired olfactory discrimination	Orbital	Jones-Gotman and Zatorre, 1993
Disorders associated with damage to the facial area	Face	Taylor, 1979

difficulty ordering the various components of the sequence into a chain of movements. The components were recalled correctly but in the wrong order. To be sure, these patients made other sorts of errors as well, especially errors of memory in which items were not recalled. The reproduction of movement sequences requires temporal memory, and our impression is that the largest deficits come from dorsolateral lesions.

The observation that frontal injury severely disrupts the copying of facial but not arm movements implies that the frontal lobe may play a special role in the control of the face, perhaps even including the tongue. We shall see in the next section that patients with frontal-lobe damage exhibit relatively little spontaneous facial expression—a result in accordance with the possible special role of the frontal lobe in the control of the face.

Voluntary Gaze

A number of studies using quite different procedures have been reported in which frontal-lobe lesions produce alterations in voluntary eye gaze. For ex-

ample, Teuber presented patients with an array of 48 patterns on a screen. The patterns could be distinguished by shape or color or both (Figure 16.5). At a warning signal, a duplicate of one of the 48 patterns appeared in the center of the array, and the subject's task was to identify the matching pattern by pointing to it. Patients with frontal-lobe lesions were impaired at finding the duplicate pattern.



Figure 16.5 Visual search task used by Teuber. The subject must locate a duplicate of the shape inside the central box by pointing to it. (After Teuber, 1964.)

Luria recorded patients' eye movements as they examined a picture of a complex scene. The eye-movement patterns of the patients with large frontal-lobe lesions were quite different from those of normal control subjects or those of patients with more-posterior lesions. For example, if a normal control was asked about the age of the people in a picture, his or her eyes fixed on the heads; if asked how they are dressed, the eyes fixed on the clothing. Patients with large frontal-lobe lesions tended to glance over the picture more or less at random, and a change in the question about the picture failed to alter the direction or the pattern of eye movements. Visual search in Luria's task would require internalized knowledge to direct the eyes.

Guitton and his colleagues examined a different type of oculomotor defect in frontal-lobe patients. They studied the ability of patients to make voluntary eye movements toward or away from briefly appearing targets presented at random to the right or the left of a fixation point. Normally, if a stimulus cue is presented briefly in either visual field, a person will make a quick eye movement (a saccade) toward the stimulus.

Patients with frontal-lobe lesions had no difficulty doing so, and so Guitton and his coworkers added a second feature to the task. Rather than making eye movements toward a target, the patients had to move their eyes to the same place in the opposite visual field. The task therefore required inhibition of the normal saccade and a voluntary saccade toward a similar point in the opposite direction.

Patients with frontal lesions had two deficits on this variation of the task. First, although normal subjects failed to inhibit a short-latency response toward the cue in about 20% of the trials, patients with frontal lesions had much more difficulty. Second, after the initial saccade in the incorrect direction, normal subjects had no difficulty in making a large corrective saccade toward the opposite field. In contrast, patients with frontal lesions, which included the frontal eye fields, had difficulty in executing the corrective response when the response had to be generated by the damaged hemisphere. In other words, they had difficulty in moving the eyes to the field contralateral to the frontal lesion. Corrective movements could be made normally in the field on the same side as the lesion.

The difficulty that patients with frontal lesions encounter in the visual-search task and in the saccade task indicates the importance of the frontal cortex for certain aspects of oculomotor control. Only the study by Guitton and associates localized the effect in the frontal eye fields, but it is likely that the most severe deficits in performing such tasks are associated with damage to those fields.

Corollary Discharge

If you push on your eyeball, the world appears to move. If you move your eyes, the world remains stable. Why? Teuber proposed that, for a movement to take place, a neural signal must produce the movement as well as a signal that the movement is going to take place. If the eyes are moved mechanically, there is

no such signal and the world moves. However, when you move your eyes, there is a neural signal that movement will happen and the world stays still. This signal has been termed **corollary discharge** or **reafference.**

Teuber argued that voluntary movements require two sets of signals rather than one. A movement command, through the motor system, effects the movements, and a signal (corollary discharge) from the frontal lobe to the parietal and temporal association cortex presets the sensory system to anticipate the motor act. Thus, a person's sensory system can interpret changes in the external world in light of information about his or her movement. For example, when you are running, the external world remains stable even though your sense organs are in motion, because the corollary discharge from the frontal lobe to the parietotemporal cortex signals that the movements are taking place. A frontal lesion therefore can not only disturb the production of a movement but also interfere with the message to the rest of the brain that a movement is taking place. By this indirect means, perception of the world by the posterior association cortex is altered.

One source of evidence that the frontal lobe plays a role in corollary discharge comes from the results of studies of cells in the frontal eye fields. Bizzi and Schiller, among others, found that some cells in the frontal eye fields fire simultaneously with movements of the eyes. These cells cannot be causing the eyes to move, because to do so they would have to fire before the eye movements (just as to accelerate an automobile, you must first depress the gas pedal). Rather, these cells must be monitoring the ongoing movement—a process suspiciously similar to what would be expected from a region controlling corollary discharge.

Speech

Speech is an example of movement selection. Passingham suggested that words are responses generated in the context of both internal and external stimuli. If the frontal lobe has a mechanism for selecting responses, then it must select words, too. The frontal lobe contains two speech zones: Broca's area, which can be regarded as an extension of the lateral premotor area, and the supplementary speech area, which may be an extension of the supplementary motor area (see Figure 16.1D).

Viewed in this way, Broca's area has a critical role when a word must be retrieved on the basis of an object, word, letter, or meaning. That is, like the premotor area's role in other behaviors, Broca's area selects words on the basis of cues. In contrast, the supplementary speech area is required to retrieve words without external cues, which also is consistent with the general function of the supplementary motor area.

People with strokes in Broca's area are impaired in their ability to use verbs and to produce appropriate grammar, a symptom known as agrammatism. People with strokes that include the supplementary speech area and extend into the left medial frontal region are often mute. The ability to speak usually returns after a few weeks in people with unilateral lesions but not in those with bilateral lesions. This outcome again supports the bilateral participation of the supplementary motor areas in movement selection. The role of the supplementary motor region is corroborated by the results of blood-flow studies done by Roland, who showed activation of the medial premotor area when subjects recall the months of the year, which is done without external cues.

Loss of Divergent Thinking

One of the clearest differences between the effects of parietal- and temporal-lobe lesions and the effects of frontal-lobe lesions is in performance on standard intelligence tests. Posterior lesions produce reliable, and often large, decreases in IQ scores, but frontal lesions do not. The puzzle is why patients with frontal-lobe damage appear to do such "stupid" things.

Guilford noted that traditional intelligence tests appear to measure what can be called **convergent thinking,** in the sense that there is just one correct answer to each question. Thus, definitions of words, questions of fact, arithmetic problems, puzzles, and block designs all require correct answers that are easily scored. Another type of intelligence test, in which the number and variety of responses to a single question rather than a single correct answer are emphasized, can measure **divergent thinking.** An example is a question asking for a list of the possible uses of a coat hanger. Frontal-lobe injury interferes with the intelligence required by divergent thinking, rather than the convergent type measured by standard IQ tests. Several lines of evidence support Guilford's idea.

Behavioral Spontaneity

Patients with frontal-lobe lesions have long been recognized to exhibit a loss of spontaneous speech. Various investigators have been able to quantify this loss by using tests such as the Thurstone Word-Fluency Test (also referred to as the Chicago Word-Fluency Test). Patients are asked to write or to say, first, as many words starting with a given letter as they can think of in 5 minutes and, then, as many four-letter words starting with a given letter in 4 minutes.

Patients with frontal-lobe lesions have a low output of words in this test. For example, when asked to generate as many words as he could think of beginning with a specific letter, E. L., introduced at the beginning of this chapter, sat for about 2 minutes before asking if he could use the Latin names of plants. He was assured that he could do so but, after another couple of minutes, he remarked, "I can't think of any!" He abandoned the plant names but, even with an additional 5 minutes, he could think of only six words.

Although the principal locus of this defect appears to be in the left orbital frontal region, lesions in the right orbital frontal region also may produce a marked reduction in verbal fluency. Again we see less asymmetry in the frontal lobes than we might expect. The following case is an example of low spontaneous verbal fluency resulting from a lesion of the right frontal lobe.

Mrs. P., a 63-year-old woman with a college degree, was suffering from a large astrocytoma of the right frontal lobe. Her word fluency is reproduced in Figure 16.6A. Four features of frontal-lobe damage are illustrated in her test performance:

1. Her total output of words is remarkably low: only 8 words beginning with the letter "s" and 6 words beginning with the letter "c." (Control subjects of

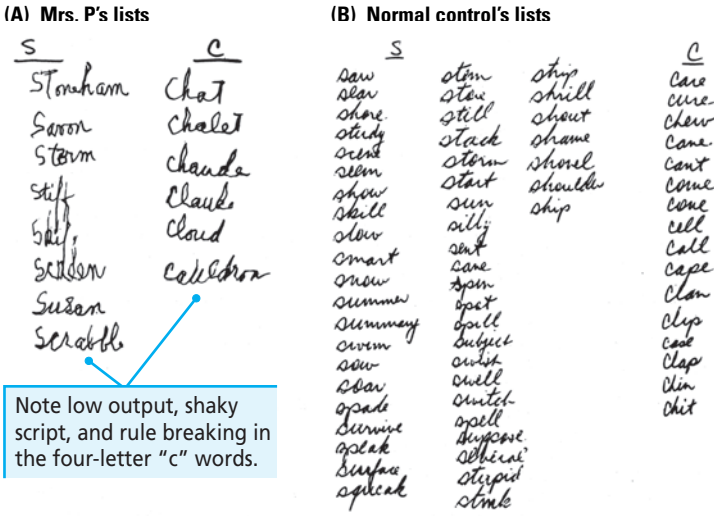

Figure 16.6 Word fluency. Subjects were given 5 minutes to write as many English words as possible starting with the letter "s" and 4 minutes to write as many four-letter words as possible starting with the letter "c."

similar age and education produce a total of about 60 words in the same time period, as shown in Figure 16.6B.)

2. Rule breaking is a common characteristic of patients on this test. We told Mrs. P. several times that the words starting with "c" could have only four letters. She replied. "Yes, yes, I know, I keep using more each time." Even though she understood the instructions, she could not organize her behavior to follow them successfully.
3. Her writing was not fluid but rather jerky, much like that seen in a child learning to write, implying that her tumor had invaded the motor or premotor cortex.
4. Mrs. P. insisted on talking throughout the test—complaining that she simply could not think of any more words—and kept looking around the room for objects starting with the required letter.

A study by Jones-Gotman and Milner raises the question of whether this verbal-fluency deficit might have a nonverbal analogue. The researchers devised an ingenious experiment in which they asked patients to draw as many different designs as they could in 5 minutes. The drawings were not supposed to be representational of anything, but rather much like the doodles that students are prone to put in the margins of their notes or textbooks. The patients were then asked to draw as many different designs as they could, but this time using only four lines (a circle was counted as a single line).

The results show a beautiful analogue to the verbal-fluency results. As can be seen in Figure 16.7, lesions in the right frontal lobe produced a large decrease in the number of different drawings produced. Normal controls drew about 35 drawings, left-frontal-lobe patients drew about 24 drawings, and right-frontal-lobe patients drew about 15 drawings. This deficit appears to be related to an impoverished output, high perseveration, and, in some cases, the drawing of nameable things (that is, representational drawings). As with verbal fluency, lesions in the orbital cortex or central facial area in the frontal lobe appeared to produce a larger deficit than did the more-dorsal lesions.

It seems likely that frontal-lobe patients show reduced spontaneity not only in speech or doodling but in their behaviors in general. For example, Kolb and Taylor recorded the spontaneous behavior of frontal-lobe patients taking a battery of neuropsychological tests. Patients with frontal-lobe removals displayed fewer spontaneous facial movements and expressions than did normal controls or patients with more-posterior lesions. In addition, there were dramatic differences in the number of words spoken by the patients in a neuropsychological interview: patients with left frontal removals rarely spoke, whereas patients with right frontal lesions were excessively talkative.

Although the range of behaviors studied to date is small, there is reason to believe that frontal-lobe patients have a general loss of spontaneous behavior. Frontal-lobe patients characteristically appear lethargic or lazy: they often have difficulty getting out of bed in the morning, getting dressed, or initiat-

Figure 16.7 Design fluency. In an analog to the word-fluency test, subjects were allowed 5 minutes to draw as many nonrepresentational doodles as they could.

(A) Normal subject



(B) Frontal lobe patient showing perseveration

(C) Frontal lobe patient showing lack of spontaneity

ing other daily activities such as going to work. One patient is a particularly dramatic example. He was a prominent lawyer who suffered a midline meningioma in the frontal lobe. The tumor was removed surgically, but he was left with bilateral damage to the superior aspect of both frontal lobes.

His IQ score was still superior (higher than 140), and his memory for legal matters was unimpaired. Nonetheless he was unable to function in his profession, because he could not get up in the morning to go to work, preferring to stay in bed and watch television. When his wife forced him to get up and go to work, he was disruptive at the office because he could not concentrate on any law-related work. Rather, he was distracted by anything else going on in the office. Curiously, he remained an excellent resource for his colleagues, who nonetheless found his behavior intolerable and consequently preferred to consult him by telephone.

Strategy Formation

Patients with frontal-lobe lesions are especially impaired at developing novel cognitive plans or strategies for solving problems. For example, when Shallice and Evans asked subjects questions that required reasoning based on general knowledge for which no immediate obvious strategy was available, they found that frontal-lobe patients did very poorly and often gave bizarre responses. In a later study, Shallice and Burgess gave patients a task very much like our dinner-party problem. The subjects were given a list of six errands (for example, "Buy a loaf of brown bread") and an instruction to be at a particular place 15 minutes after starting. They were also to get answers to four questions (for instance, the price of a pound of tomatoes). They were not to enter shops except to buy something and were to complete the tasks as quickly as possible, without rushing.

The frontal-lobe patients found this simple task very difficult. They were inefficient, they broke rules (for example, entered unnecessary shops), and two of the three patients failed at least four of the tasks. Yet, when quizzed, all the patients understood the task and attempted to comply. Similar difficulty with everyday problems is seen in a study by Smith and Milner. They asked subjects to estimate the average price of a particular object, such as a sewing machine. They suggested that to perform such a task one must develop a strategy that might include deciding what a typical sewing machine is, judging the range of possible prices, and selecting a representative price for a machine of average quality. They found that patients with frontal-lobe lesions—especially right frontal lesions—were very poor at this task. In contrast, patients with temporal-lobe damage who showed memory deficits on other tasks performed like controls on this task. Thus, it seems unlikely that a simple explanation of impaired memory will account for the poor performance of the frontal-lobe patients.

Shallice and Burgess argued that, although the frontal lobe may have a general role in planning behavior, it has a critical role in coping with novel situations in contrast with routine ones. They suggested that coping with a novel situation, by which they mean a novel set of external and internal states, entails the activation of a wide variety of processes to solve the problem. In contrast, the solution of a familiar task can rely on strategies that have been well practiced and therefore are more easily accessed.

The extreme case of novel situations is during development, when most situations are novel. Hebb noted in the 1940s that, relative to frontal-lobe injuries acquired in adulthood, people whose frontal-lobe injuries were acquired in childhood often show surprisingly severe deficits in behavioral control. He believed that these people were not able to properly develop the behavioral schematas necessary to solve problems. That is, they would find few situations routine.

Environmental Control of Behavior: Impaired Response Inhibition and Inflexible Behavior

Perhaps the most commonly observed trait of frontal-lobe patients is their difficulty in using information from environmental cues (feedback) to regulate or change their behavior. This difficulty manifests itself in a number of ways.

Response Inhibition

Patients with frontal-lobe lesions consistently perseverate on responses in a variety of test situations, particularly those in which there are changing demands. The best example of this phenomenon is observed in the Wisconsin Card-Sorting Test, which has become one of the standard clinical tests of frontal-lobe injury. As Figure 16.8 shows, a subject is presented with four stimulus cards, bearing designs that differ in color, form, and number of elements. The subject's task is to sort the cards into piles in front of one or another of the stimulus cards. The only help given the subject is to be told whether the choice is correct or incorrect.

The test works on the following principle: the correct solution is, first, color; when the subject has figured out this solution, the correct solution then becomes, without warning, form. Thus, the subject must now inhibit classifying the cards on the basis of color and shift to form. When the subject has succeeded at selecting by form, the correct solution again changes unexpectedly, this time to the number of elements. It will later become color again, and so on.

Shifting response strategies is particularly difficult for people with frontal lesions. They may continue responding to the original stimulus (color) for as many as 100 cards until testing is terminated. Throughout this period, they may comment that they know that color is no longer correct. They nevertheless continue to sort on the basis of color. For example, one person stated (correctly): "Form is probably the correct solution now so this [sorting to color] will be wrong, and this will be wrong, and wrong again."

Such perseveration is common on any task in which a frontal-lobe patient is required to shift response strategies, demonstrating that the frontal lobe is necessary for flexibility in behavior. It is important to note that, on card-sorting tasks, the subjects must not be given any hint that they are to expect a change in the correct solution, because many frontal-lobe patients improve dramatically when given this warning. The cue apparently allows enough flexibility in behavior to solve the problem.

From the results of Milner's work, the principal locus of this card-sorting effect appears to be roughly around Brodmann's area 9 in the left hemisphere. Lesions elsewhere in the left frontal lobe, and often in the right, will also produce a deficit on this task, although an attenuated one.

Figure 16.8 The Wisconsin Card-Sorting Test, showing test material as presented to the subject. The task is to place each card from the bottom pile with the appropriate card in the top row, sorting by one of three possible categories: color, number of elements, or shape. Subjects are never told the correct sorting category but only whether their responses are correct or incorrect. When the subject selects the correct category, the correct solution changes unexpectedly. (After Milner, 1964.)

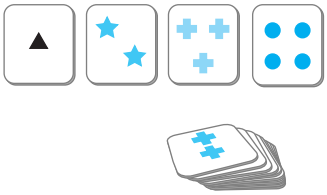

Performance of the Stroop Test (Figure 16.9) further demonstrates loss of response inhibition subsequent to frontal-lobe damage. Subjects are presented with a list of color words (blue, green, red, and so forth), each word being printed in colored ink but never in the color denoted by the word (for example, the word "yellow" is printed in blue, green, or red ink). The subject's task is to name the color in which each word is printed as quickly as possible. Correct response requires the inhibition of reading the color name, an inhibition that is difficult for many control subjects. Perret found that patients with left frontal lesions were unable to inhibit reading the words and thus were impaired in this task.

BLUE WHITE
BLACK GRAY
GRAY WHITE
BLUE BLACK

Figure 16.9 The Stroop test. The task is to give the color of the ink for each word as quickly as possible. When the ink color and the color name are the same, the task is simple. When they are different, there is a tendency to read the word rather than give the ink color.

Risk Taking and Rule Breaking

Frontal-lobe patients are distinguished from other patients in their common failure to comply with task instructions. Milner found this failure to comply to be especially common on tests of stylus-maze learning in which a buzzer indicates that the patient has made an error and is to stop and start at the beginning of the maze again. Subjects with frontal-lobe lesions tended to disregard the signal, thereby continuing the incorrect path and making more errors. This behavior is reminiscent of their inability to modify their responses in the card-sorting task.

Miller gave subjects a task in which words had to be guessed on the basis of partial information. With each additional clue, a subject was assigned a successively lower point value for a correct answer, but points could be collected only if the answer was correct. An incorrect answer forfeited all the points for an item. Frontal-lobe patients took more risks (and made more mistakes) than did other patients, and the risk taking was greatest in those frontal-lobe patients who also had temporal-lobe damage.

The role of the orbital frontal cortex in risk taking has been studied extensively by Antoine Bechera, Antonio Damasio and their colleagues, who designed a gambling task in which subjects gradually learn how to play a unique card game. They are presented with four decks of cards and are asked to turn over the first card in any deck. Some cards are associated with a payoff ($50 or $100), whereas other cards result in a $50 or $100 penalty being assessed. Each subject is given $2000 in play money to play the game, and the goal is to make as much money in the game as possible.

The trick in the game is that the reward and penalty contingencies of each deck differ. For example, one deck may have high payoffs but also has high penalties, whereas another may have a lower payoff but also a low penalty. The game is set so that playing two of the four decks results in a net loss, whereas playing the other two yields a net gain.

The results from the Bechera studies are clear: normal subjects and patients without frontal damage sample from all the decks for a while but quickly learn which decks have the best payoff. In contrast, patients with orbital frontal injuries do not learn this strategy and play predominantly from the bad decks, thus losing all their money. An important aspect of the task is that subjects are not allowed to keep a running tally of how they are doing; rather they must "sense" which decks are risky and which are profitable. This ability is clearly a function of the prefrontal cortex and its loss makes it difficult for orbital frontal patients to make wise decisions, especially in social or personal matters—that is, situations in which an exact calculation of future outcomes is not possible.

Self-regulation

We noted earlier that people with ventral frontal injuries, such as M. L., have deficits in the self-regulation of behavior in unstructured situations, in part because of a loss of autonoetic awareness. M. L. had been a salesman, and he knew what his job had been and that he had traveled a great deal. When pressed, however, he was unable to provide a single personal example of this job. For example, when asked if he traveled to conferences, he said that, yes, he traveled to conferences often; it was a major part of his job. Yet he could not name a single instance of an experience at a conference. His autobiographical knowledge was lost.

You can imagine what this impairment would be like if you think about your high-school experience. We are all aware of having gone to high school and can describe what high school was like, and presumably so could patients such as M. L. The difference, however, is that we can describe personal events that happened in high school, whereas M. L. would not be able to do so. We can immediately see why M. L. had difficulty in relating to his wife—he simply could not recall instances that would explain why they were married.

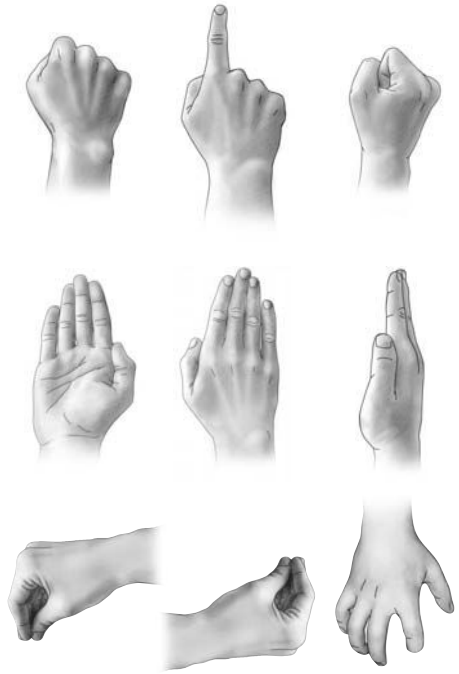

Figure 16.10 The nine hand postures that constitute responses in the Petrides experiments. In these studies, subjects had to learn to associate each hand posture with one of nine different colors and to perform the movement in response to the presentation of the appropriate color.

Associative Learning

Patients with large frontal-lobe lesions have often been claimed to be unable to regulate their behavior in response to external stimuli—that is, to learn from experience. Luria and Homskaya described patients with massive frontal-lobe tumors who could not be trained to respond consistently with the right hand to a red light and with the left hand to a green light, even though the patients could indicate which hand was which and could repeat the instructions.

In an extensive series of studies, Petrides examined the ability of both human patients and monkeys with frontal lesions to make arbitrary stimulus-response associations. In one study, Petrides asked frontal-lobe patients to learn arbitrary associations between colors and hand postures, as illustrated in Figure 16.10. For example, patients were presented with nine colored stimuli, and the their task was to learn which posture was associated with which colored stimulus. Damage to either the left or the right hemisphere resulted in poor performance on this task. Again, the behavioral impairments in the frontal-lobe patients could not be attributed to a deficit in memory, because temporal-lobe patients who performed poorly on other tests of memory performed normally at these tasks. Rather, the problem is in learning to select, from a set of competing responses, the appropriate ones for the various stimuli.

Poor Temporal Memory

Perhaps the single most important experimental discovery for understanding the functions of the frontal lobe was Carlyle Jacobsen's finding that chimpanzees with frontal-lobe lesions were impaired in the delayed-response test. In this task, an animal observes a reward being placed under a plaque, in a well. The chimp's view is blocked for a few seconds, and then it is allowed to retrieve the reward. Animals with prefrontal lesions perform at chance, even with extended practice. Although the behavioral impairment is unlikely to be due to a

single deficit, the deficit is difficult to interpret without recourse to some sort of memory difficulty. Four additional experiments are especially germane here.

In the first experiment, Passingham presented monkeys with a task in which the animals were required to open each of 25 doors to obtain a food reward. Food was placed behind each door only once per day; so the animals had to learn not to return to locations where the reward had been obtained already. Passingham found that lesions in area 46 produced marked impairments in this task. Thus, whereas the normal monkeys developed a door-opening strategy that led to few repetitions, the lesioned animals were inefficient, often returning to previously accessed doors (Figure 16.11A).

In the second experiment, Funahashi, Bruce, and Goldman-Rakic trained monkeys to fixate on a central spot of light while target lights were flashed in different parts of the visual field. The monkeys had to wait for the fixation spot to disappear before moving their eyes to the spot where the target light had been flashed. The researchers found that unilateral lesions in the principal sulcus (part of area 46) impaired the monkeys' ability to remember the location of the target in a restricted region of the contralateral visual field, as illustrated in Figure 6.11B. They interpret this result as showing that the principal sulcus contains a mechanism for guiding responses on the basis of stored information, which in this case is spatial.

The third experiment was conducted by Mishkin and Manning. They trained monkeys in a task known as delayed nonmatching to sample. In this test, a monkey is confronted with an unfamiliar object, which it displaces to

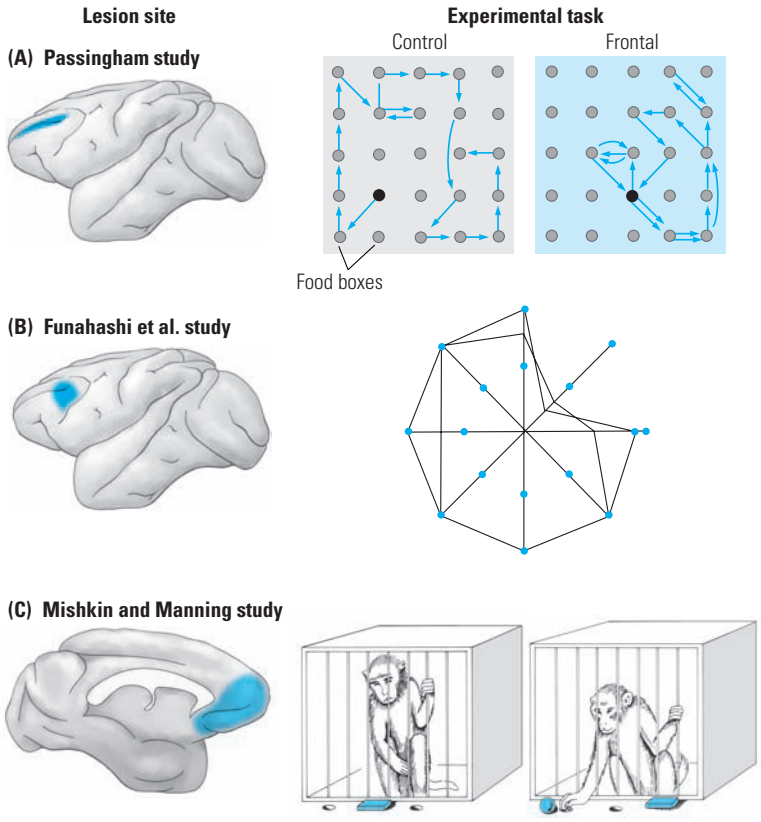

Figure 16.11 Testing for temporal memory. Schematic illustrations of frontal lesions in monkeys are shown at the left. The shaded areas represent lesion sites in three experiments, illustrated on the right, that reveal a temporal memory deficit. (A) Passingham study. (B) Funahashi et al. study. (C) Mishkin and Manning study.

1 The task is to retrieve a food reward from each of 25 food boxes. Notice that the control animal seldom returns to a previously visited location, whereas the monkey with a sulcus principalis lesion makes numerous errors.

2 The task is to fixate at the central point, and then after a 3 sec delay move the eye to locate the place where a target light had flashed. Correct performance percentage is indicated by the relative positions of the lines along axes drawn through the central fixation point. Note that the monkey performed poorly in one region of the visual field contralateral to the lesion.

3 The monkey is shown an object, which is displaced, and a food reward is obtained. The monkey is then presented with two objects after a short delay; the task is to obtain a reward, which is under the novel object. Monkeys with medial lesions are impaired at this task, which is nonspatial.

find a reward. After a delay the animal sees the same object paired with a new one. The monkey must recognize the object that it saw earlier and move the new one instead to get a reward (Figure 6.11C). Monkeys with lesions of areas 10 and 32 are impaired in this task. Mishkin and Manning interpret this result as showing that this area of the frontal cortex participates in the short-term storage of object information.

The fourth experiment was a 1991 study by Petrides in which monkeys were given two different tasks. In the first task, the animals were presented with three objects and allowed to choose one for reward. The animals were then given an option between the chosen object and one of the other objects, with the correct choice being the one that was not previously selected. In the second task, the animals were again presented with three objects and allowed one choice. On this task, however, they were then presented with the previously selected object and a novel object.

In the first task, a monkey must recall what it did with the objects. In the second task, the monkey must recall only which object was seen before. Monkeys with dorsolateral lesions performed at chance on the first task but performed as well as controls on the second. This result suggests that the dorsolateral cortex plays a role in monitoring self-generated responses.

Taken together, these five experiments point to an unequivocal role for the frontal cortex in short-term memory process and to the fact that different regions of the prefrontal cortex control the storage of different types of information. In view of the anatomical connections, it seems likely that area 46 plays a role in providing an internal representation of spatial information and that the medial regions play a similar role with object information.

The results of electrophysiological studies lend further support for the role of area 46: cells in this area are active during the intervals in delayed-response tests and their activity ends abruptly when the animal responds. Some neurons respond selectively to the spatial position of the cues, and we might expect to find similar neurons coding some features of objects as well.

Studies of temporal memory have taken a slightly different slant with human subjects. On the basis of earlier works by others, Milner, Corsi, and Leonard designed an ingenious test of memory for the order in which things have happened, which is often called recency memory. Subjects were shown a long series of cards, each card bearing two stimulus items, which were either words or pictures. On some cards a question mark appeared between the items, and the subjects' task was to indicate which of the two items had been seen more recently. Successful performance required the subjects to recall the order of presentation of the stimuli.

On most test trials, both the items had appeared previously, but, on some, one item was new. In this case, the task became one of simple recognition memory. Patients with frontal-lobe lesions performed normally on the recognition trials, but they were impaired in judging the relative recency of two previously seen items. Further, there is relative asymmetry in the frontal lobes in this regard: the right frontal lobe appears to be more important for memory for nonverbal or pictorial recency; the left frontal lobe appears to be more important for verbal recency. In contrast, patients with temporal-lobe lesions were impaired in the recognition test but not in the recency test. (This latter finding is curious, because it seems to be analogous to blindsight in that people who fail to recognize items can identify which was observed most recently.

Might this suggest a memory location system that is separate from a memory recognition system?)

Petrides and Milner designed an experiment that is conceptually similar to Passingham's self-ordering task for monkeys. Subjects were presented with stacks of cards on which were displayed an array of 12 stimuli, including words or drawings in parallel versions of the task. The stimuli in the array remained constant, but the position of each stimulus varied randomly from card to card. The subjects' task appeared rather simple: go through the stack and point to only one item on each card, taking care not to point to the same item twice. Thus, the subjects themselves initiated the plan to follow and determined the order of responding. Although the task appears easy to us, frontal-lobe patients did not find it so: left-frontal-lobe lesions were associated with impaired performance of both verbal and nonverbal versions of the task, whereas right-frontal-lobe lesions were associated with poor performance only on the nonverbal test.

Petrides and Milner suggested that, in contrast with the recency tests, the self-ordered tasks require subjects to organize and carry out a sequence of responses. From the moment the subjects begin to respond, they must constantly compare the responses that they have made with those that still remain to be carried out. Hence, the self-ordered task demands an accurate memory as well as an organized strategy.

When questioned about their approach to the task at the end of testing, patients with frontal lesions were less likely than other subjects to report that they had used a particular strategy, and, when they had, the strategy often appeared to be ill defined and to have been used inconsistently. The deficit is unlikely to have been one of simple memory, because temporal-lobe patients, who would have been expected to have defects of memory, performed normally at this task.

The temporal memory deficits in both laboratory animals and in human patients have caught the imagination of researchers for more than 60 years. Recently, both imaging studies and single-unit studies in monkeys have confirmed what the lesion studies had suggested—namely, that the prefrontal cortex plays a critical role in temporal memory. A study by Fuster and colleagues serves as a nice illustration. In this experiment, monkeys were trained to associate two different tones each with one of two different colors, as illustrated in Figure 16.12. The trick was that a monkey heard the tone and then had to remember which tone it had heard for 10 seconds before making a response to obtain reward. A large contingent of cells in dorsolateral prefrontal area (areas 8, 9, and 46) responded selectively to one tone or the other and, later, to its associated color. These cells appear to integrate sound and color across time. Curiously, in trials on which the animals made errors, the cells failed to respond, indicating no temporal correlation of the sound and color.

Figure 16.12 Prefrontal cells that code sensory associations.

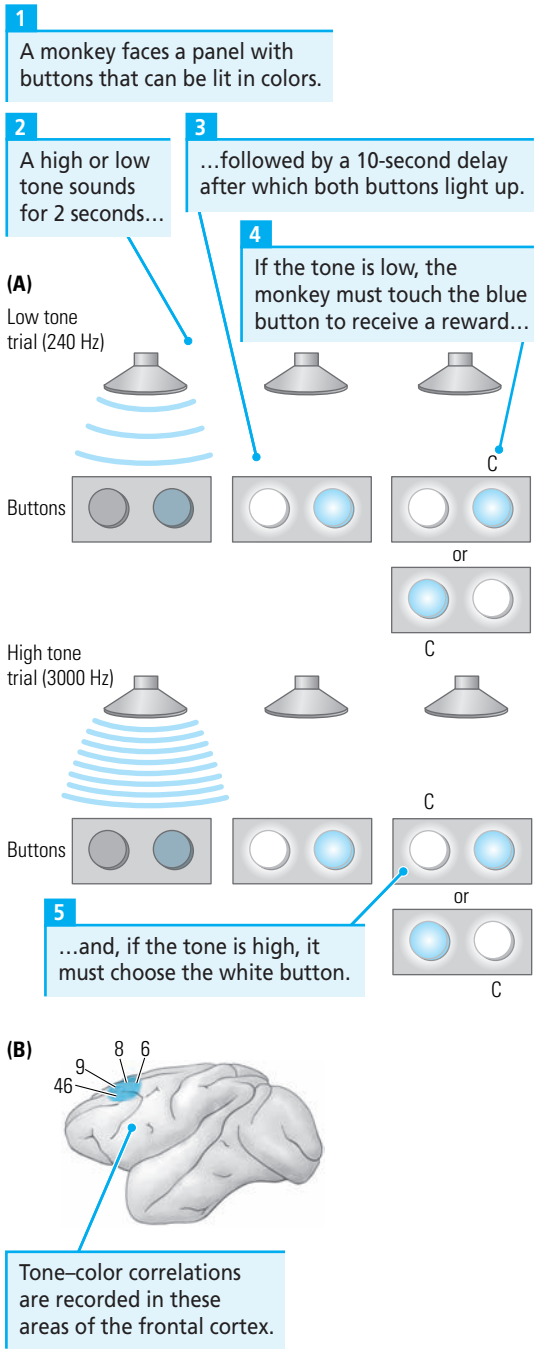

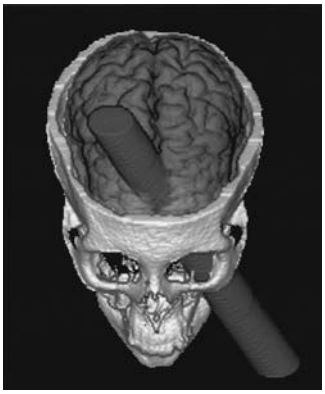

Figure 16.13 When Phineas Gage died in 1861, no autopsy was performed, but his skull was later recovered. Measurements from Gage's skull were combined with imaging techniques to reconstruct the accident and determine the probable location of the lesioning. The image makes it obvious that the frontal cortex of both hemispheres was damaged. (Department of Neurology and Image Analysis Facility, University of Iowa.)

Impaired Social and Sexual Behavior

Social and sexual behaviors require flexible responses that are highly dependent on contextual cues. It is hardly surprising, therefore, that frontal-lobe lesions interfere with both. Perhaps the most obvious and striking effect of frontal-lobe damage in humans is a marked change in social behavior and personality. The most publicized example of personality change subsequent to frontal-lobe lesions is that of Phineas Gage, first reported by John Harlow in 1868. Gage was a dynamite worker who survived an explosion that blasted an iron tamping bar (about a meter long and 3 centimeters wide at its widest point) through the front of his head (Figure 16.13). After the accident, his behavior changed completely. Gage had been of average intelligence and was "energetic and persistent in executing all of his plans of operation." His personality after the injury was described by Harlow as follows:

> The equilibrium or balance, so to speak, between his intellectual faculties and animal propensities seems to have been destroyed. He is fitful, irreverent, indulging at times in the grossest profanity, manifesting but little deference to his fellows, impatient of restraint or advice when it conflicts with his desires, at times pertinaciously obstinate, yet capricious and vacillating, devising many plans of operation, which are no sooner arranged than they are abandoned in turn for others appearing more feasible. A child in his intellectual capacity and manifestations, he has the animal passions of a strong man. (Blumer and Benson, 1975, p. 153)

Gage's injury affected primarily the left frontal lobe from the medial orbital region upward to the precentral region. Although Gage's skull has been examined carefully, the first person with extensive frontal damage to undergo close scrutiny at autopsy was a furrier who fell 30 meters from a window. He suffered a compound fracture of the frontal bones and severe injury to the right frontal lobe but, remarkably, was never unconscious and was confused only briefly. Before the fall, the man had been good natured and sociable, but, afterward, he became nasty and cantankerous. Autopsy, about a year after the accident, revealed deep scarring of the orbital part of both frontal lobes, although it was more extensive on the right.

From 1900 until about 1950, there were many excellent psychiatric studies of the effect of brain lesions on personality. A consistent finding of this work (especially Kleist's, cited in Zangwill) was that damage to the orbital regions of the frontal lobe is associated with more-dramatic changes in personality than are dorsolateral lesions, although the latter also have significant effects. Clinical descriptions of the effects of frontal-lobe lesions on personality abound, but there are few systematic studies.

At least two types of personality change have been clinically observed in such patients: Blumer and Benson have termed them **pseudodepression** and **pseudopsychopathy.** Patients classified as being pseudodepressed exhibit such symptoms as outward apathy and indifference, loss of initiative, reduced sexual interest, little overt emotion, and little or no verbal output. Patients classified as pseudopsychopathic exhibit immature behavior, lack of tact and restraint, coarse language, promiscuous sexual behavior, increased motor activity, and a general lack of social graces. Two case histories illustrate these personalities.

Pseudodepression

At the age of 46, a successful salesman sustained a compound depressed fracture of the left frontal bone in a traffic accident. Treatment included debridement [surgical removal] and amputation of the left frontal pole. Recovery was slow, and 9 months after the injury he was referred for long-term custodial management. By this time, he had recovered motor function with only a minimal limp and slight hyperreflexia on the right side, had normal sensation, no evidence of aphasia, and normal memory and cognitive ability (IQ 118). Nonetheless, he remained under hospital care because of marked changes in personal habits.

Prior to the accident, the patient had been garrulous, enjoyed people, had many friends and talked freely. He was active in community affairs, including Little League, church activities, men's clubs, and so forth. It was stated by one acquaintance that the patient had a true charisma, "whenever he entered a room there was a change in the atmosphere, everything became more animated, happy and friendly."

Following the head injury, he was quiet and remote. He would speak when spoken to and made sensible replies but would then lapse into silence. He made no friends on the ward, spent most of his time sitting alone smoking. He was frequently incontinent of urine, occasionally of stool. He remained unconcerned about either and was frequently found soaking wet, calmly sitting and smoking. If asked, he would matter-of-factly state that he had not been able to get to the bathroom in time but that this didn't bother him. Because of objectionable eating habits he always ate alone on the ward. His sleep pattern was reversed; he stayed up much of the night and slept during the day. He did not resent being awakened or questioned. He could discuss many subjects intelligently, but was never known to initiate either a conversation or a request. He could give detailed accounts of his life prior to the accident, of the hospitals he had been in, the doctors and treatment he had had, but there was an unreality to his conversation. When asked, he would deny illness, state emphatically that he could return to work at any time, and that the only reason he was not working was that he was being held in the hospital by the doctors. At no time did he request a discharge or weekend pass. He was totally unconcerned about his wife and children. Formerly a warm and loving father, he did not seem to care about his family. Eventually, the family ceased visiting because of his indifference and unconcern. (Blumer and Benson, 1975, pp. 156–157)

Pseudopsychopathy

A 32-year-old white male was admitted for behavioral evaluation. History revealed that he had sustained a gunshot wound in Vietnam 5 years previously. A high-velocity missile had entered the left temple and emerged through the right orbit. Infection necessitated surgical removal of most of the orbital surface of the right frontal lobe. On recovery, he was neither paralyzed nor aphasic but suffered a remarkable change in personality.

Prior to injury he had been quiet, intelligent, proper, and compulsive. He was a West Point graduate and spent the ensuing years as a military officer attaining the rank of captain. Both as a cadet and later

> as an officer, he was known to be quiet, strict, and rigid. He was considered a good commander, trusted by his men, but never shared camaraderie with his troops or with his peers.
>
> Subsequent to injury, he was outspoken, facetious, brash, and disrespectful. There was no evidence of self-pity, although he frequently made rather morbid jokes about his condition (for example, "dummy's head"). On admission to the hospital, he had just failed at an extremely simple job.
>
> He was not aphasic but misused words in a manner that suggested inability to maintain specific meanings. For instance, when asked whether the injury had affected his thinking his response was, "Yeah—it's affected the way I think—it's affected my senses—the only things I can taste are sugar and salt—I can't detect a pungent odor—ha ha—to tell you the truth it's a blessing this way." When the examiner persisted, "How had it affected the way you think?" his response was "Yes—I'm not as spry on my feet as I was before." He was never incontinent, but did show a messiness in attire. His remarks to the nurses and other female personnel were open and frank but were never blatantly sexual. His premorbid IQ was reported at about 130. Present examination showed a full-scale IQ of 113. (Blumer and Benson, 1974, pp. 155–156)

Blumer and Benson are probably correct in their assertion that all elements of these syndromes are observable only after bilateral frontal-lobe damage. Nevertheless, some elements of these two rather different syndromes can be observed in most, if not all, persons with unilateral frontal-lobe lesions. Pseudodepression appears most likely to follow lesions of the left frontal lobe, pseudopsychopathic behavior to follow lesions of the right frontal lobe.

Changes in sexual behavior are among the most difficult symptoms of frontal-lobe damage to document properly, largely because of social taboos against investigating people's sexual lives. To date, there are no such empirical studies, but there is anecdotal evidence that frontal lesions do alter libido and related behavior. Orbital frontal lesions may introduce abnormal sexual behavior (such as public masturbation) by reducing inhibitions, although the frequency of sexual behavior is not affected. On the other hand, dorsolateral lesions appear to reduce interest in sexual behavior, although patients are still capable of the necessary motor acts and can perform sexually if led through the activity "step by step."

The results of several studies show that frontal-lobe lesions in monkeys significantly alter social behavior. In one interesting study, Butter and Snyder removed the dominant (so-called alpha) male from each of several groups of monkeys. They removed the frontal lobes from half of these alpha monkeys. When the animals were later returned to their groups, they all resumed the position of dominant male, but within a couple of days all the monkeys without frontal lobes were deposed and fell to the bottom of the group hierarchy.

Analogous studies of wild monkeys have shown similar results: monkeys with frontal-lobe lesions fall to the bottom of the group hierarchy and eventually die, because they are helpless alone. Exactly how the social behavior of these animals changed is not known, but there is little doubt that the changes are as dramatic as those in the social behavior of humans. The social interactions of monkeys are complex and include a significant amount of context-dependent behavior; the behavior of a monkey will change in accord with the

configuration of the proximal social group, and monkeys may lose this ability after frontal-lobe lesions. There are likely to be additional components of this behavioral change, however, that relate to the interpretation of species-typical sensory cues, whether they be odors, facial expressions, or sounds.

The deficit in the perception of facial expression by frontal-lobe patients may be related to the loss of cells that code for facial expression. Certain cells in the temporal lobe are especially responsive to facial expression (see Chapter 15), and Rolls and his colleagues showed that a population of cells in the orbital frontal cortex also codes for faces. Some of these face-selective neurons are responsive to facial expression or movement. It is thus not surprising that patients with orbital frontal lesions might have difficulty in understanding facial expression. We could speculate that there are also likely to be cells in the prefrontal cortex that are responsive to tone of voice, which would be a verbal analogue of facial expression.

Is There a Spatial Deficit?

We have indicated that a key to understanding the functions of the dorsolateral cortex is to be found in its relation to the posterior parietal cortex. The posterior parietal cortex plays a central role in visuomotor guidance of movements in space, and region PG and the superior temporal sulcus play some role in more-complex spatial behavior such as mental rotation (see Chapter 14). These parietotemporal regions provide a major input into the dorsolateral region, which implies some role of this frontal area in spatially guided behavior.

The precise role has been difficult to determine, however. It is clear that dorsolateral lesions impair short-term memory for the location of events, and this deficit presumably could interfere with the selection of behaviors with respect to places in space. Indeed, the delayed-response deficit, as well as the deficit in Passingham's and Goldman-Rakic's tasks (see Figure 16.11), have spatial components.

The role of the dorsolateral cortex in "spatial thinking" can also be seen in a blood-flow study by Roland and Frieberg. They asked subjects to imagine walking along a familiar route and taking first a left turn, then a right, and so on, alternating turns along the path. A major increase in blood flow in the dorsolateral region suggests a role for the dorsolateral cortex in the selection of spatially guided behaviors.

Taken together, results of the blood-flow and lesion studies suggest that the frontal lobe has a role in selecting between different visual locations. This role may be related to some aspect of attention, an idea that we return to in Chapter 22. Note, however, that little evidence favors the role of the prefrontal cortex in parietal-lobe functions such as topographic orientation or in the ability to mentally manipulate or organize spatial information (see Chapter 14).

Symptoms Associated with Damage to the Facial Area

Through the years, Taylor and his colleagues have accumulated some remarkable data from a small group of patients with localized surgical removals of the precentral and postcentral gyri, containing, respectively, the motor and sensory representations of the face (see Figure 16.1D). Unlike the removal of cortical areas for the hand, the removal of areas for the face is seldom associated with long-lasting somatosensory deficits on the face, even if both the sensory and

the motor representations are removed completely. This finding is in keeping with the evidence that the face is represented bilaterally in the cortex.

There has been no systematic study of the facial motor abilities of patients who have undergone the removal of both precentral and postcentral gyri, but Kolb and Milner found such patients able to perform facial-movement sequences normally. Furthermore, although these patients had difficulty in making individual facial movements in the initial postoperative period, especially on the side of the face contralateral to the lesion, they appeared to have regained normal voluntary facial control a month after surgery, although closer examination might have revealed subtle defects. In addition, their faces were expressive, and they displayed normal spontaneous facial expressions at frequencies well within normal limits.

In the immediate postoperative period, patients with left-hemisphere facial-area lesions are aphasic, being impaired at both language comprehension and language production, as well as being alexic. However, these symptoms subside rapidly, probably having resulted from swelling and trauma associated with the surgical procedure. Within about 6 months to a year after surgery, only a slight residual expressive dysphasia remains. Yet these same patients are severely impaired at certain other language tests. In particular, they perform very poorly on tests of word fluency and are unable to make effective use of the phonetic elements of language.

In addition, these same patients are very poor spellers, occasionally writing words that are unrecognizable. Their low verbal fluency is complemented by a very low design fluency (see Figure 16.7). Patients with right facial-area lesions are worse at design fluency than are patients with very large anterior frontal lesions. This lack of spontaneity in verbal and design fluency is remarkable, considering the normal spontaneity of facial expressions.

In summary, unilateral removal of the cortical area representing the face results in no significant chronic loss in sensory or motor control of the face, presumably because of the face's bilateral representation in the cortex. But it does result surprisingly in chronic deficits in phonetic discrimination, spelling, verbal fluency, and design fluency. Taylor has preliminary data suggesting that these deficits may result primarily from damage to the precentral motor representation of the face, rather than from damage to the postcentral sensory representation. The origin of these deficits, however, is unexplained to date.

Clinical Neuropsychological Assessment of Frontal-Lobe Damage

Considering the number and variety of symptoms associated with frontal-lobe damage, surprisingly few standardized neuropsychological tests are useful for assessing frontal-lobe function. Furthermore, some of the symptoms of frontal-lobe injury, such as the loss of self- regulation of behavior, are not easily assessed by a neuropsychological test. Nonetheless, there are a number of very good clinical tests, which are summarized in Table 16.3. As with the parietal- and temporal-lobe tests discussed in Chapters 14 and 15, for a person to perform normally on all these tests if there were damage to either frontal lobe would be highly unusual.

The Wisconsin Card-Sorting Test (see Figure 16.8) is the best available test of dorsolateral frontal cortex function. As described earlier, a subject is told to sort the cards into piles in front of one or another of the stimulus cards bearing designs that differ in color, form, and number of elements. The correct so-

Table 16.3 Standardized clinical neuropsychological tests for frontal-lobe damage

Function	Test	Basic reference
Response inhibition	Wisconsin Card Sorting	Milner, 1964
	Stroop	Perret, 1974
Verbal fluency	Thurstone Word Fluency	Milner, 1964
		Ramier and Hecaen, 1970
Nonverbal fluency	Design Fluency	Jones-Gotman and Milner, 1977
Motor	Hand dynamometry	Taylor, 1979
	Finger tapping	Reitan and Davison, 1974
	Sequencing	Kolb and Milner, 1981
Language comprehension	Token	de Renzi and Faglioni, 1978
	Spelling	Taylor, 1979
	Phonetic discrimination	Taylor, 1979
Working memory	Self-ordering	Owen et al., 1990
		Pouchon et al., 2001
Planning	Tower of London	Owen et al., 1995

lution shifts without the subject's knowledge when he or she has figured out each solution.

Recall that the Thurstone Word-Fluency Test requires subjects to say or write as many words beginning with a given letter as possible in 5 minutes, and then as many four-letter words beginning with a given letter in 4 minutes (see Figure 16.6). Although subjects with lesions anywhere in the prefrontal cortex are apt to do poorly on this test, subjects with facial-area lesions perform the worst, and those with orbital lesions perform only slightly better. Performance is poorest when the lesion is in the left hemisphere.

The Gotman-Milner Design-Fluency Test (see Figure 16.7) also is very useful, although somewhat difficult to score. Subjects are asked to draw as many unnameable, abstract drawings as they can in 5 minutes. Frontal-lobe patients will draw very few items, draw nameable objects, or draw the same figure repeatedly. Like the verbal-fluency tests, the design-fluency task appears most sensitive to orbital injury.

Two tests, the Tower of Hanoi and the Tower of London, have proved sensitive to frontal injury, although the Tower of London appears to be a purer test of planning functions. In both tests, a person is presented with several pegs and several discs of varying size. The discs must be moved from the presented location to another configuration and location according to different rules. For example, only one disc can be moved at a time, and a large disc may never be placed on a smaller one. Damage to either the left or the right prefrontal cortex produces impairments on these tasks.

Tests of motor function include tests of strength (hand dynamometry), finger-tapping speed, and movement sequencing. Strength and finger-tapping speed are significantly reduced contralaterally to a lesion that is in the vicinity of the precentral or postcentral gyri. Motor sequencing can be assessed by using Kolb and Milner's facial-sequence test, although this test requires considerable practice to administer and scoring should be from videotaped records. Simpler tests of movement programming such as the Kimura Box Test

(see Chapter 14) are not suitable, because frontal-lobe patients are unlikely to perform very poorly unless the lesion extends into the basal ganglia.

As in preceding chapters, we recommend the token test as a quick screening test for aphasia, to be followed if necessary by more-extensive aphasia testing (see Chapter 19). Although damage to Broca's area is widely believed to result in deficits only in language production and not in comprehension, this outcome is not strictly true. Left frontal lesions in the vicinity of Broca's area produce deficits in comprehension as well as in production.

Spelling is seriously impaired by facial-area lesions and can be assessed by any standardized spelling test. Phonetic differentiation, a test described by Stitt and Huntington and used for neurological patients by Taylor, is another means of assessing facial-area function. A series of nonsense words, such as "agma," is presented and a subject's task is to identify the first consonant sound. This test proves difficult even for controls, but it is performed most poorly by subjects with facial-area damage, especially damage on the left side. However, frontal-lobe lesions outside the facial area also may impair performance on this test significantly.

In the absence of language deficits, localizing frontal-lobe damage in either the left or the right hemisphere with neuropsychological tests may prove to be difficult, presumably because the functions of the two frontal lobes overlap significantly. Clinical evaluation of personality as pseudodepressed or pseudopsychopathic (as discussed earlier) may prove useful in localizing the dysfunction to the left or the right hemisphere, respectively, but caution is advised. Unfortunately, no standardized quantitative measures of these symptoms are available.

Imaging Frontal-Lobe Function

In general, the results of imaging studies have shown specific activation for prefrontal functions that were identified historically in lesion studies, as illustrated in Table 16.4. Thus, for example, the results of many studies have shown dorsolateral prefrontal participation in tasks tapping verbal and nonverbal working temporal memory. An especially intriguing finding, however, comes

Table 16.4 Examples of functional imaging studies of frontal-lobe function

Presumed function	Locus of activation	Basic reference
Self-ordering	Dorsolateral	Petrides, 2000
Conditioned learning	Dorsolateral	
Spatial working memory	Dorsolateral; Ventrolateral	Owen et al., 1996
Visuomotor skill learning	Dorsolateral	Doyon et al., 1996
Verbal memory retrieval	Dorsolateral	Buckner et al., 1995 Tulving et al., 1994
	Ventrolateral	Petrides et al., 1995
Encoding visual information	Orbital frontal	Frey and Petrides, 2000
Encoding unpleasant auditory information	Orbital frontal	Frey et al., 2000
Facial expression or recognition or both	Inferior prefrontal	Idaka et al., 2001

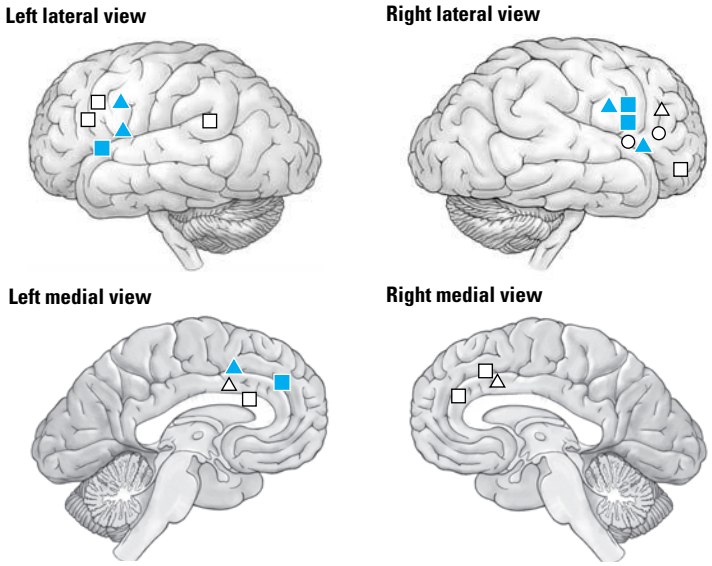

KEY
- ○ Auditory discrimination
- ● Visual divided attention
- △ Self-paced response production
- ▲ Task switching
- □ Spatial problem solving
- ■ Semantic processing of words

Figure 16.14 Prefrontal activations produced by widely different cognitive demands. Shown are lateral and medial views of each hemisphere. Despite the diversity of cognitive demands in these experiments, frontal activations show apparent clustering, with most points within middorsolateral, midventrolateral, and dorsal anterior cingulate regions.

from a review by Duncan and Owen. They reviewed the patterns of frontal-lobe activation associated with a broad range of different cognitive demands, including aspects of perception, response selection, executive functions, working memory, long-term memory, and problem solving.

Given such a diverse set of presumed cognitive functions, one can reasonably imagine that different regions of the frontal lobe are active during the performance of cognitive tasks that require different cognitive functions. The surprising finding, however, is that a striking regularity in activation emerged: for most cognitive demands, there was a similar recruitment of the dorsolateral, ventrolateral, and anterior cingulate regions, as summarized in Figure 16.14. The reviewers concluded that, although regional specialization exists within the frontal lobe, a frontal lobe network is consistently recruited for the solution of a diverse set of cognitive problems. How these three regions work in concert to produce behavior is not immediately obvious, but the overlap of activation in such diverse cognitive processes makes it easy to see how the frontal lobe is central to the control of such a diversity of behavior.

Diseases Affecting the Frontal Lobe

Many symptoms of frontal-lobe injury are characteristic of people with psychiatric or neurological disorders, including especially schizophrenia (see Chapter 20), Parkinson's disease (see Chapter 22), and Korsakoff's disease (see Chapter 18). In each case, a disturbance of frontal-lobe function likely contributes significantly to the behavioral symptoms of the disease.

In schizophrenia, there are believed to be an abnormality in the mesocortical dopamine projection, which terminates largely in the frontal lobe, a decrease in blood flow to the frontal lobe, and possible frontal-lobe atrophy. Schizophrenic patients perform poorly on all tests of frontal-lobe function and exhibit abnormalities in the control of eye movements, but they perform normally on tests of parietal-lobe function.

Parkinson's disease results from a loss of the dopamine cells of the substantia nigra. Although the primary projection of these cells is to the caudate nucleus, they project directly to the prefrontal cortex, too, and indirectly through the dorsomedial nucleus of the thalamus. Parkinson patients are characterized by a lack of facial expression similar to that seen in frontal-lobe patients, and they are impaired in the Wisconsin Card-Sorting Test and at delayed-response tasks.

Korsakoff patients suffer from alcohol-induced damage to the dorsomedial thalamus and may have a deficiency in catecholamines in the frontal cortex. They perform poorly on the Wisconsin Card-Sorting Test, as well as on tests of spatial memory such as delayed response.

Summary

The frontal lobe can be conceived as the end point for the visuomotor and object-recognition functions that are initiated in the occipital lobe. The frontal lobe's function in these processes is to select behaviors with respect to context and internalized knowledge.

It is possible to subdivide the frontal lobe into three distinct functional zones: motor cortex, premotor cortex, and prefrontal cortex. The motor cortex is responsible for making movements. The premotor cortex selects movements. The prefrontal cortex controls the cognitive processes so that appropriate movements are selected at the correct time and place. The premotor cortex can be divided into two regions: the lateral area responsible for selecting behaviors in response to environmental cues and the supplementary area responsible for selecting behaviors on the basis of internalized knowledge. The prefrontal cortex can be divided into two general zones: a dorsolateral zone responsible for selecting behavior with respect to temporal memory and the inferior prefrontal region responsible for selecting behavior with respect to context. Context may be current or based on previous knowledge, including self-knowledge.

The wide range of symptoms of frontal-lobe lesions can be grouped, conceptually, into several categories: (1) disturbances of motor functions; (2) loss of divergent thinking; (3) impaired response inhibition and inflexible behavior; (4) poor temporal memory; and (5) impaired social and sexual behavior imaging.

There is a complementary effect of left and right frontal lesions, in that left frontal lesions are more likely to affect language or movement-related behaviors, and right frontal lesions are more likely to alter nonlanguage functions, such as emotion.

The results of imaging studies show frontal participation in tasks with widely different cognitive demands including attentional tasks, sensory discrimination tasks, motor tasks, spatial problem solving; and semantic processing of words. Dysfunction of the frontal lobe is implicated in many behavioral disorders, including particularly schizophrenia, Parkinson's disease, and Korsakoff's disease.

References

Bechara, A., D. Tranel, and H. Damasio. Characterization of the decision-making deficit of patients with ventromedial prefrontal cortex lesions. *Brain* 123:2189–2202, 2000.

Benton, A. L. Differential effects of frontal lobe disease. *Neuropsychologia* 6:53–60, 1968.

Bizzi, E., and P. H. Schiller. Single unit activity in the frontal eye fields of unanesthetized monkeys during head and eye movement. *Experimental Brain Research* 10:151–158, 1970.

Blumer, D., and D. F. Benson. Personality changes with frontal and temporal lobe lesions. In D. F. Benson and D. Blumer, Eds. *Psychiatric Aspects of Neurologic Disease.* New York: Grune & Stratton, 1975.

Brown, J. W. *Aphasia, Apraxia, and Agnosia: Clinical and Theoretical Aspects.* Springfield, IL: Charles C. Thomas, 1972.

Buckner, R. L., M. E. Raichle, and S. E. Petersen. Dissociation of human prefrontal cortical areas across different speech production tasks and gender groups. *Journal of Neurophysiology* 74:2163–2173, 1995.

Butter, C. M., and D. R. Snyder. Alterations in aversive and aggressive behaviors following orbital frontal lesions in rhesus monkeys. *Acta Neurobiologiae Experimentalis* 32:525–565, 1972.

Deiber, M.-P., R. E. Passingham, J. G. Colebatch, K. J. Friston, P. D. Nixon, and R. S. J. Frackowiak. Cortical areas and the selection of movement: A study with positron emission tomography. *Experimental Brain Research* 84:393–402, 1991.

de Renzi, E., and P. Faglioni. Normative data and screening power of a shortened version of the token test. *Cortex* 14:41–49, 1978.

Doyon J., R. Laforce, G. Bouchard, D. Gaudreau, J. Roy, M. Poirier, P. J. Bedard, F. Bedard, and J. P. Bouchard. Role of the striatum, cerebellum and frontal lobes in the automatization of a repeated visuomotor sequence of movements. *Neuropsychologia* 36:625–641, 1998.

Doyon, J., A. M. Owen, M. Petrides, V. Sziklas, and A. C. Evans. Functional anatomy of visuomotor skill learning in human subjects examined with positron emission tomography. *European Journal of Neuroscience* 8:637–648, 1996.

Drewe, E. A. Go–no-go learning after frontal lobe lesions in humans. *Cortex* 11:8–16, 1975.

Duncan, J., and A. M. Owen. Common origins of the human frontal lobe recruited by diverse cognitive demands. *Trends in Neuroscience* 23:475–483, 2000.

Freedman, M., and M. Oscar-Berman. Bilateral frontal lobe disease and selective delayed response deficits in humans. *Behavioral Neuroscience* 100:337–342, 1986a.

Freedman, M., and M. Oscar-Berman. Comparative neuropsychology of cortical and subcortical dementia. *Canadian Journal of Neurological Science* 13(4 Suppl):410–414, 1986b.

Frey, S., and M. Petrides. Orbitofrontal cortex: A key prefrontal region for encoding information. *Proceedings of the National Academy of Sciences of the United States of America* 97:8723–8727, 2000.

Frey, S., P. Kostopoulous, and M. Petrides. Orbitofrontal involvement in the processing of unpleasant auditory information. *European Journal of Neuroscience* 12:3709–3712, 2000.

Funahashi, S., C. J. Bruce, and P. S. Goldman-Rakic. Perimetry of spatial memory representation in primate prefrontal cortex. *Society for Neuroscience Abstracts* 12:554, 1986.

Fuster, J. M. The prefrontal cortex—an update: Time is of the essence. *Neuron* 30:319–333, 2001.

Fuster, J. M., M. Bodner, and J. K. Kroger. Cross-modal and cross-temporal association in neurons of frontal cortex. *Nature* 405:347–351, 2000.

Goel, V., and J. Grafman. Are the frontal lobes implicated in "planning" functions? Interpreting data from the Tower of Hanoi. *Neuropsychologia* 5:623–642, 1995.

Goldman-Rakic, P. S. Circuitry of the primate prefrontal cortex and regulation of behavior by representational memory. In F. Plum, Ed. *Handbook of Physiology; The Nervous System*, vol. 5, *Higher Functions of the Brain*, Part 1. Bethesda, MD: American Physiological Society, 1987.

Guilford, J. P. *The Nature of Human Intelligence.* New York: McGraw-Hill, 1967.

Guitton, D., H. A. Buchtel, and R. M. Douglas. Disturbances of voluntary saccadic eye-movement mechanisms following discrete unilateral frontal-lobe removals. In G. Lennerstrand, D. S. Lee, and E. L. Keller, Eds. *Functional Basis of Ocular Motility Disorders.* Oxford: Pergamon, 1982.

Iidaka, T., M. Omori, T. Murata, H. Kosaka, Y. Yonekura, T. Okada, and N. Sadato. Neural interaction of the amygdala with the prefrontal and temporal cortices in the processing of facial expressions as revealed by fMRI. *Journal of Cognitive Neuroscience* 15:1035–1047, 2001.

Jacobsen, C. F. Studies of cerebral function in primates. *Comparative Psychology Monographs* 13:1–68, 1936.

Jenkins, I. H., R. E. Passingham, P. D. Nixon, R. S. J. Frackowiak, and D. J. Brooks. The learning of motor sequences: A PET study. *European Journal of Neuroscience* (Suppl. 5):3215, 1992.

Jones-Gotman, M., and B. Milner. Design fluency: The invention of nonsense drawings after focal cortical lesions. *Neuropsychologia* 15:653–674, 1977.

Jones-Gotman, M., and R. J. Zatorre. Odor recognition memory in humans: Role of right temporal and orbitofrontal regions. *Brain and Cognition* 22:182–198, 1993.

Kolb, B., and B. Milner. Performance of complex arm and facial movements after focal brain lesions. *Neuropsychologia* 19:505–514, 1981.

Kolb, B., and B. Milner. Observations on spontaneous facial expression after focal cerebral excisions and after

intracarotid injection of sodium amytal. *Neuropsychologia* 19:514–515, 1981.

Kolb, B., and L. Taylor. Affective behavior in patients with localized cortical excisions: An analysis of lesion site and side. *Science* 214:89–91, 1981.

Kuypers, H. G. J. M. Anatomy of the descending pathways. In V. B. Brooks, Ed. *Handbook of Physiology; The Nervous System*, vol. 2, *The Motor Systems.* Baltimore: Williams & Wilkins, 1981.

Lashley, K. S. The problem of serial order in behavior. In F. A. Beach, D. O. Hebb, C. T. Morgan, and H. W. Nissen, Eds. *The Neuropsychology of Lashley.* New York: McGraw-Hill, 1960.

Lepage, M., Ghaffar, O., Nyberg, L., and E. Tulving. Prefrontal cortex and episodic memory retrieval mode. *Proceedings of the National Academy of Sciences of the United States of America* 97:506–511, 2000.

Leonard, G., L. Jones, and B. Milner. Residual impairment in handgrip strength after unilateral frontal-lobe lesions. *Neuropsychologia* 26:555–564, 1988.

Levine, B., S. E. Black, R. Cabeza, M. Sinden, A. R. Mcintosh, J. P. Toth, E. Tulving, and D. T. Stuss. Episodic memory and the self in a case of isolated retrograde amnesia. *Brain* 121:1951–1973, 1998.

Luria, A. R. *The Working Brain.* New York: Penguin, 1973.

Luria, A. R., and E. D. Homskaya. Disturbance in the regulative role of speech with frontal lobe lesions. In J. M. Warren and K. Akert, Eds. *The Frontal Granular Cortex and Behavior.* New York: McGraw-Hill, 1964.

Miller, L. Cognitive risk taking after frontal or temporal lobectomy I: The synthesis of fragmented visual information. *Neuropsychologia* 23:359–369, 1985.

Miller, L., and B. Milner. Cognitive risk taking after frontal or temporal lobectomy II: The synthesis of phonemic and semantic information. *Neuropsychologia* 23:371–379, 1985.

Milner, B. Some effects of frontal lobectomy in man. In J. M. Warren and K. Akert, Eds. *The Frontal Granular Cortex and Behavior.* New York: McGraw-Hill, 1964.

Milner, B., P. Corsi, and G. Leonard. Frontal cortex contribution to recency judgements. *Neuropsychologia* 29:601–618, 1991.

Milner, B., and M. Petrides. Behavioural effects of frontal-lobe lesions in man. *Trends in Neurosciences* 7:403–407, 1984.

Mishkin, M., and F. J. Manning. Non-spatial memory after selective prefrontal lesions in monkeys. *Brain Research* 143:313–323, 1978.

Owen, A. M., J. J. Downes, B. J. Sahakian, C. E. Polkey, and T. W. Robbins. Planning and spatial working memory following frontal lobe lesions in man. *Neuropsychologia* 28:1021–1034, 1990.

Owen, A. M., B. Milner, M. Petrides, and A. C. Evans. Memory for object features versus memory for object location: A positron-emission tomography study of encoding and retrieval processes. *Proceedings of the National Academy of Sciences of the United States of America* 93:9212–9217, 1996.

Owen, A. M., B. J. Sahakian, J. R. Hodges, R. A. Summers, C. E. Polkey, and T. W. Robbins. Dopamine-dependent fronto-striatal planning deficits in early Parkinson's disease. *Neuropsychology* 9:126–140, 1995.

Passingham, R. E. Memory of monkeys (*Macaca mulatta*) with lesions in prefrontal cortex. *Behavioral Neuroscience* 99:3–21, 1985.

Passingham, R. E. *The Frontal Lobes and Voluntary Action.* Oxford: Oxford University Press, 1993.

Perret, E. The left frontal lobe of man and the suppression of habitual responses in verbal categorical behavior. *Neuropsychologia* 12:323–330, 1974.

Petrides, M. Motor conditional associative learning after selective prefrontal lesions in the monkey. *Behavioural Brain Research* 5:407–413, 1982.

Petrides, M. Functional specialization within the dorsolateral frontal cortex for serial order memory. *Proceedings of the Royal Society, London* B246:299–306, 1991.

Petrides, M. Visuo-motor conditional associative learning after frontal and temporal lesions in the human brain. *Neuropsychologia* 35:989–997, 1997.

Petrides, M. Mapping prefrontal cortical systems for the control of cognition. In A. W. Toga and J. C. Mazziotta, Eds. *Brain Mapping: The Systems.* San Diego: Academic Press, 2000, pp. 159–176.

Petrides, M., B. Alivisatos, and A. C. Evans. Functional activation of the human ventrolateral frontal cortex during mnemonic retrieval of verbal information. *Proceedings of the National Academy of Sciences of the United States of America* 92:5803–5807, 1995.

Petrides, M., and B. Milner. Deficit on subject ordered tasks after frontal- and temporal-lobe lesions in man. *Neuropsychologia* 20:249–262, 1982.

Potter, H., and N. Butters. An assessment of olfactory deficits in patients with damage to prefrontal cortex. *Neuropsychologia* 18:621–628, 1980.

Pouchon, J.-B., R. Levy, J.-B Poline, S. Crozier, S. Lehericy, B. Pillon, B. Deweer, D. Le Bihan, and B. Dubois. The role of dorsolateral prefrontal cortex in the preparation of forthcoming actions: An fMRI study. *Cerebral Cortex* 11:260–266, 2001.

Ramier, A.-M., and H. Hecaen. Role respectif des atteintes frontales et de la lateralisation lesionnelle dans les deficits de la "fluence verbale." *Revue de Neurologie* 123:17–22, 1970.

Reitan, R. M., and L. A. Davison. *Clinical Neuropsychology: Current Status and Application.* New York: Wiley, 1974.

Roberts, A. C., T. W. Robbins, and L. Weizkrantz, Eds. *The Prefrontal Cortex: Executive and Cognitive Functions.* Oxford: Oxford University Press, 1998.

Roland, P. E. Metabolic measurements of the working frontal cortex in man. *Trends in Neuroscience* 7:430–435, 1984.

Roland, P. E., and L. Friberg. Localization of cortical areas activated by thinking. *Journal of Neurophysiology* 3:1219–1243, 1985.

Roland, P. E., B. Larsen, N. A. Lassen, and E. Skinhoj. Supplementary motor area and other cortical areas in organization of voluntary movements in man. *Journal of Neurophysiology* 43:118–136, 1980.

Rolls, E. T. The orbitofrontal cortex. In A. C. Roberts, T. W. Robbins, and L. Weizkrantz, Eds. *The Prefrontal Cortex: Executive and Cognitive Functions.* Oxford: Oxford University Press, 1998, pp. 67–86.

Rolls, E. T. *The Brain and Emotion.* Oxford: Oxford University Press, 2000.

Rose, J. E., and C. N. Woolsey. The orbitofrontal cortex and its connections with the mediodorsal nucleus in rabbit, sheep and cat. *Research Publications of the Association of Nervous and Mental Disease* 27:210–232, 1948.

Semmes, J., S. Weinstein, L. Ghent, and H.-L. Teuber. Impaired orientation in personal and extrapersonal space. *Brain* 6:747–772, 1963.

Shallice, T. *From Neuropsychology to Mental Structure.* Cambridge, UK: Cambridge University Press, 1988.

Shallice, T., and P. Burgess. Deficits in strategy application following frontal lobe damage in man. *Brain* 114:727–741, 1991.

Shallice, T., and M. E. Evans. The involvement of the frontal lobes in cognitive estimation. *Cortex* 14:294–303, 1978.

Smith, M. L., and B. Milner. Differential effects of frontal-lobe lesions on cognitive estimation and spatial memory. *Neuropsychologia* 22:697–705, 1984.

Stitt, C., and D. Huntington. Some relationships among articulation, auditory abilities, and certain other variables. *Journal of Speech and Learning Research* 12:576–593, 1969.

Taylor, L. Psychological assessment of neurosurgical patients. In T. Rasmussen and R. Marino, Eds. *Functional Neurosurgery.* New York: Raven, 1979.

Teuber, H.-L. The riddle of frontal lobe function in man. In J. M. Warren and K. Akert, Eds. *The Frontal Granular Cortex and Behavior.* New York: McGraw-Hill, 1964.

Teuber, H.-L. Unity and diversity of frontal lobe function. *Acta Neurobiologiae Experimentalis* 32:615–656, 1972.

Tulving, E. Episodic memory: From mind to brain. *Annual Review of Psychology* 53:1–25, 2002.

Tulving E., S. Kapur, F. I. Craik, M. Moscovitch, and S. Houle. Hemispheric encoding/retrieval asymmetry in episodic memory: Positron emission tomography findings. *Proceedings of the National Academy of Sciences of the United States of America* 91:2016–2020, 1994.

Tyler, H. R. Disorders of visual scanning with frontal lobe lesions. In S. Locke, Ed. *Modern Neurology.* London: Churchill, 1969.

Walker, E. A., and D. Blumer. The localization of sex in the brain. In K. J. Zulch, O. Creutzfeldt, and G. C. Galbraith, Eds. *Cerebral Localization.* Berlin and New York: Springer-Verlag, 1975.

Zangwill, O. L. Psychological deficits associated with frontal lobe lesions. *International Journal of Neurology* 5:395–402, 1966.